



click to campus

INI CET 2023 Question Paper

Graduate Aptitude Test in Engineering (GATE)

Paper	Page No.
INI CET 2023 Question Paper - Set 1	2 - 17
INI CET 2023 Question Paper - Set 2	18 - 24

Download more INI CET Previous Year Question Papers: [Click Here](#)

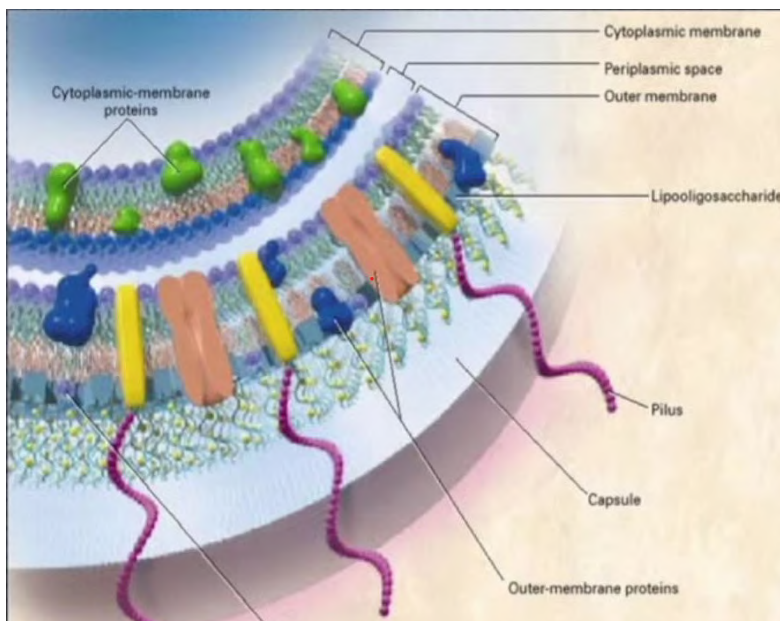
INI CET 2023 Question Paper (Memory-Based)

Pathology and Microbiology

Ques. TOXOPLASMOSIS.. Infective form in cat faeces?

- A. Oocyst
- B. Bradyzoite
- C. Tachyzoite
- D. ..

Ques. IBQ

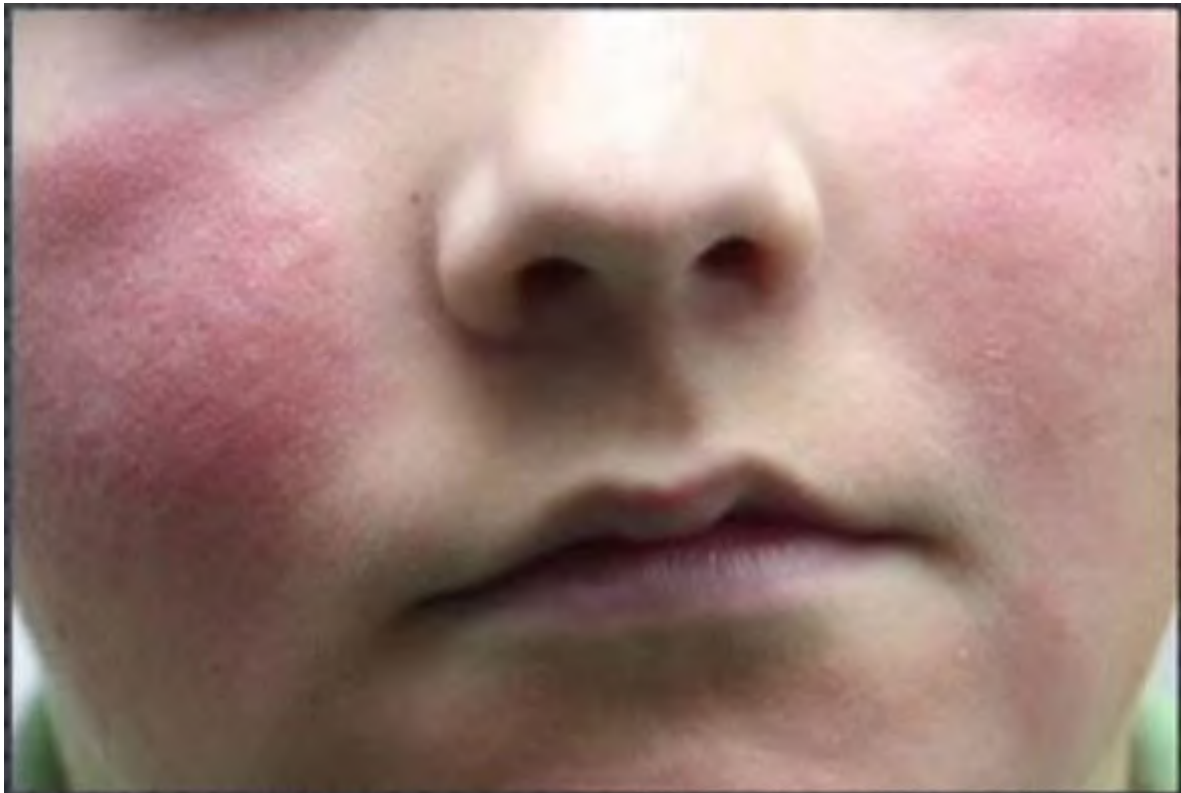

- A. E.coli
- B. Neisseria meningitidis
- C. Staphylococcus
- D. Pseudomonas

Ques. In absence of CD40, which of the following would not occur?

- A. Class switching/ Hyper IgM syndrome
- B. ..

Ques.IBQ



Slapped cheek appearance

Which of the following haematological abnormalities can be associated with this infection ?

- A. Pure red cell aplasia
- B. ..

Ques. Gram positive bacilli with motility.

- A. Listeria- tumbling motility= motile at 22 degree and non motile at 37 degree

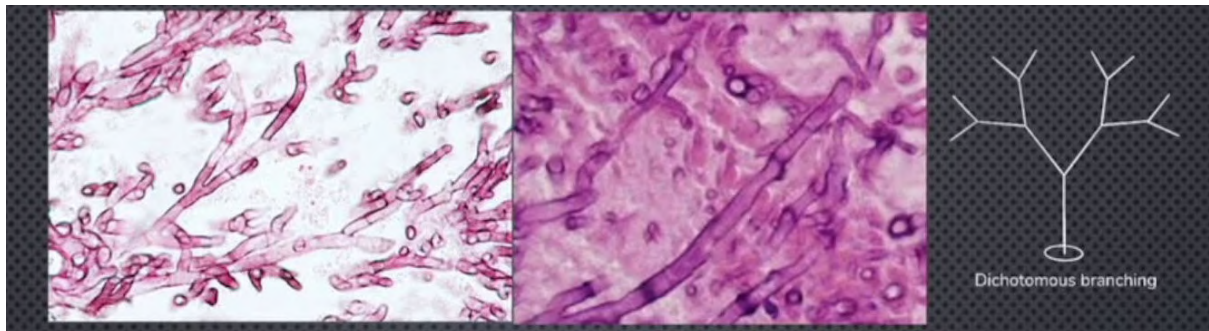
B. ..

Ques. Match the following- incubation periods

Ans.

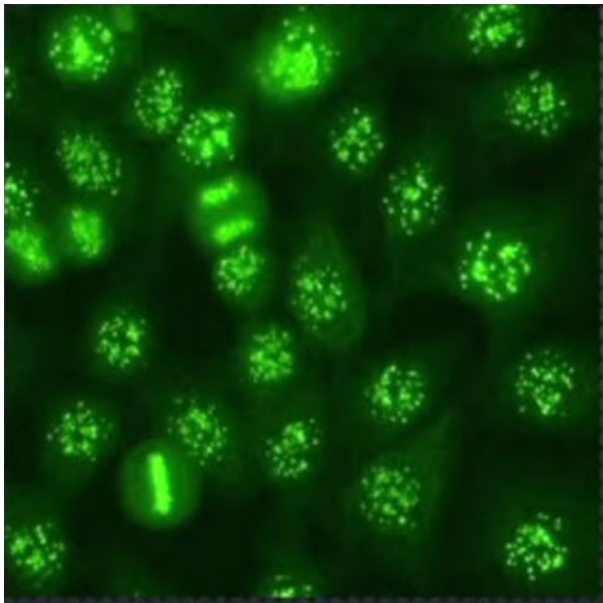
- A. Syphilis= 9-90 days
- B. SARS CoV2= 10 days
- C. Chicken pox= 14-21 days
- D. Hepatitis A= 50 days

Ques. IBQ



- A. Aspergillus
- B. .

Ques. Following ANA Pattern if it's seen, identify the pattern?

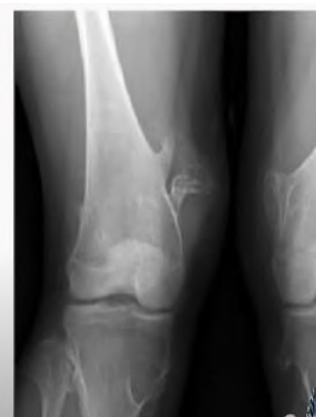

- A. NUCLEOLAR
- B. SPECKLED
- C. CENTROMERIC
- D. DIFFUSE

..
..
..

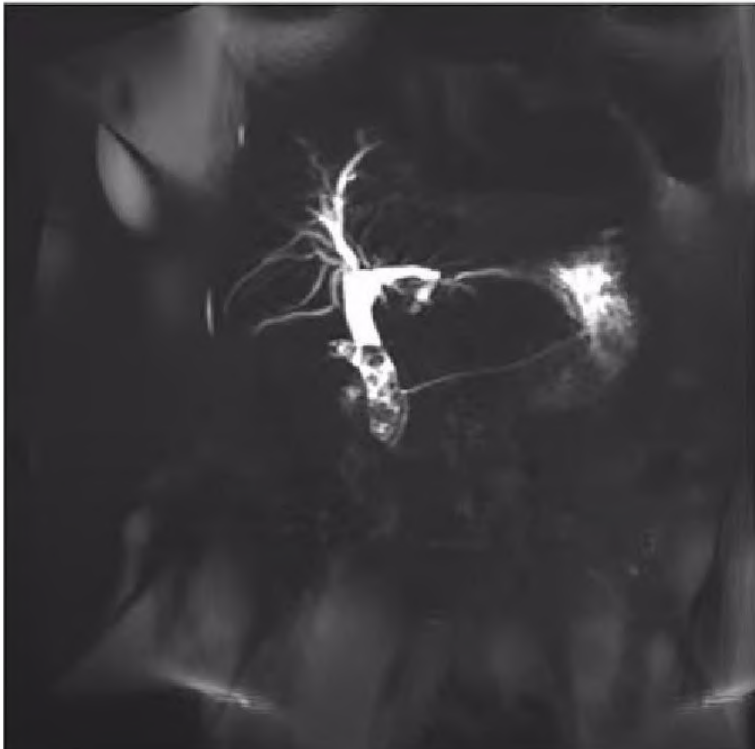
Radiology

Ques. Which of the following points are in favour of the malignancy of the given X-ray?



- A. Growth along medullary cavity
- B. Hyaline cap thickness >2 cm
- C. Infection of the adjoining bone
- D. None of the above

Ques. What is the diagnosis of the case shown in the image below?

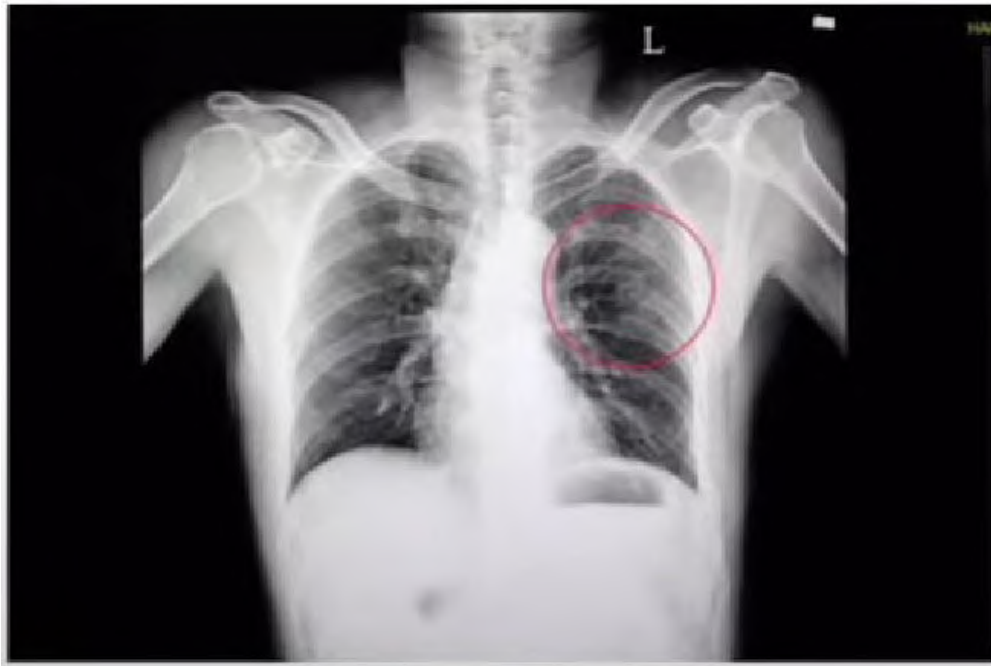


- A. Choledocholithiasis
- B. CBD Stricture
- C. Cholelithiasis
- D. Pancreatic duct calculi

Ques. What is not an advantage of USG over mammography:

- A. USG can be used to detect mammography undetectable tumours which are palpable.
- B. Can be used to differentiate solid vs cystic lesions.
- C. Can be used for guided biopsy.
- D. In young females with dense breast

Ques. A young patient met with a road traffic accident and now presented to the casualty and a chest Xray was performed. Which of the ribs are fractured?



- A. 4,5,6,7
- B. 3,4,5,6
- C. 2,3,4,5
- D. 1,3,4,5

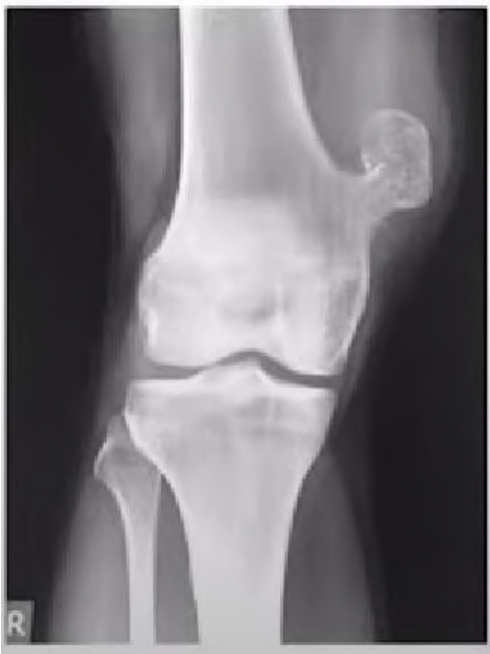Ques. Match the following with their regards to thyroid swelling obstruction:

A) Trachea	1) Dysphagia
B) Oesophagus	2) Hoarseness of voice
C) Recurrent laryngeal nerve	3) Horner's Syndrome
D) Sympathetic chain	4) Dyspnea

Select the correct answer from the given below code:

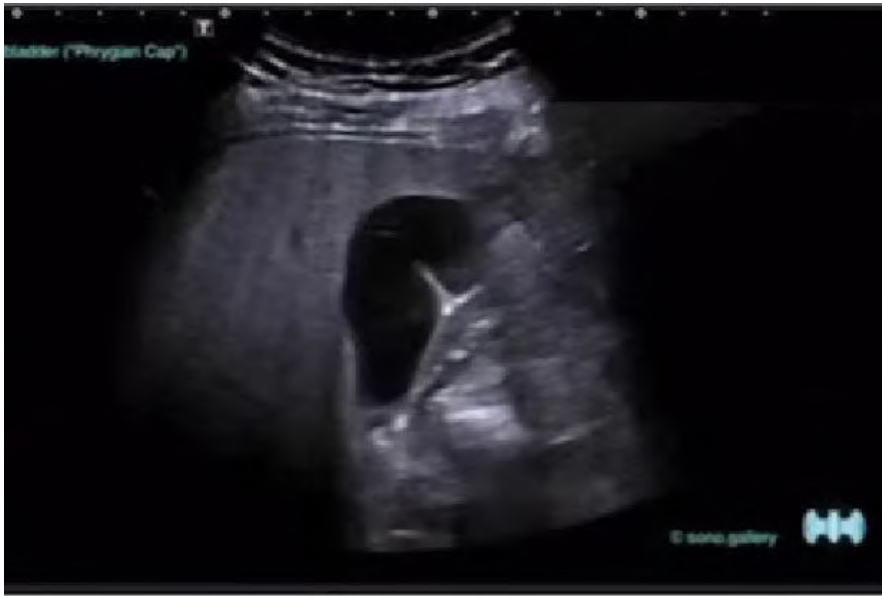- A. A2, B4, C1, D3
- B. A1, B2, C3, D4
- C. A4, B1, C2, D3
- D. A4, C1, B2, D3

Ques. A young patient presented with a swelling above the knee joint which was increasing slowly for the last few years and now presented with sudden increase in size. A radiograph performed showed the following findings. Which of the statements given below is correct regarding malignant transformation of the lesion?



- A. Thickness of cartilaginous cap > 2 cm on MRI
- B. Growth towards the joint instead of moving away from it.
- C. Continuation with the marrow cavity on Imaging
- D. New appearance of Pain

Ques. What is the diagnosis of the given USG image?



- A. GB Polyp
- B. Cholelithiasis
- C. Phrygian cap
- D. Floating Gallbladder

Ques. Banana sign USG is commonly seen in which of the following?

- A. Omphalocele
- B. Spina bifida
- C. Anencephaly
- D. Encephalocele

Ques. A young patient presented with mild fever and right upper quadrant pain for the last 7 days. On USG, a Hypoechoic lesion with irregular border is seen in posterior superior aspect of right lobe of the liver. What is the most likely diagnosis?

- A. Amoebic abscess
- B. Liver abscess

- C. Hydatid cyst &
- D. ??

Biochemistry

Ques. Which of the following deficiencies can cause Xanthinuria?

- A. Manganese
- B. Magnesium
- C. Molybdenum
- D. Zinc

Ques. Which enzyme deficiency causes Pompe's disease?

- A. Lysosomal alpha glucosidase
- B. Muscle Glycogen Phosphorylase
- C. Glucose 6 phosphatase
- D. Beta glucosidase

Ques. Xanthurenic Acid is excreted in urine due to the deficiency of?

- A. B6
- B. B1
- C. B2
- D. B12

Ques. Calculate Anion Gap:

Na: 145

K: 4

Cl: 30

HCO3: 18

- A. 35
- B. 44
- C. 28
- D. 12

Ques. True about Iron Deficiency anaemia

- A. Low Iron
- B. Low Ferritin
- C. High Total Iron Binding Capacity
- D. Low Transferrin Saturation

Ques. Template strand is 5' CGTTATTACTA3'. If this is transcribed by RNA polymerase, the sequence of the new RNA will be

- A. 5'GCAATAAATGAT3'
- B. 5'GCAAUAAAUGAUS'
- C. 5'UAGUAAAUAACG3'
- D. 5'CGUUAUUUACUA3'

Ques. Thermic effect is:

- A. Highest for fats
- B. Highest for carbohydrates
- C. Highest for proteins
- D. Equal for all the fuels

Ques. Which is false about collagen?

- A. Phenylalanine is the most abundant amino acid
- B. It is a fibrillar protein

- C. Hydroxyproline and proline are present
- D. Cross Linkage formation uses Vitamin C and Copper

Ques. A mother while kissing the child finds the sweat of the child to be salty. Which of the following channels is affected?

- A. Sodium
- B. Chloride
- C. Potassium
- D. Iodide

Ques. A young boy with Type I diabetes presents with unconsciousness. His urine is subjected to a test and the result is provided below. The test that is done is?



- A. Benedict's test
- B. Rothera's test
- C. Biuret Test
- D. Fouchet test

Ques. Barth syndrome presents with heart failure. Deficiency of which of the following structures in mitochondrial membrane is the cause of this syndrome?

- A. Lysolecithin
- B. Plasmalogen
- C. Lecithin
- D. Cardiolipin

Ques. SRY gene is located in?

- A. Long arm of chromosome X
- B. Long arm of chromosome Y
- C. Short arm of chromosome Y
- D. Short arm of chromosome X

Ques. Massive Blood Transfusion causes all of the following except:

- A. Hypokalemia
- B. Hypocalcemia
- C. Hypomagnesemia
- D. Alkalosis

Ques. Severe vomiting leads to:

- A. Hypokalemia
- B. Hypochloremia
- C. Metabolic alkalosis
- D. Respiratory Alkalosis

Ques. Liver can't utilise ketone bodies because of lack of?

- A. Thiolase
- B. Thiophorase
- C. Thioesterase
- D. HMG CoA synthase

Ques. The hormone which acts through the JAK STAT pathway is?

- A. Calcitonin
- B. Leptin
- C. Aldosterone
- D. Vasopressin

Ques. Cholestasis is mediated through defects of which of the following proteins?

- A. OAT1b1
- B. MRP3
- C. ABCA1
- D. MRP2

ENT

Ques. A 27 years old female present with thyroid swelling that compresses the nearby structures. Which of the following symptoms is not seen in this patient?

- A. Hoarseness of voice due to recurrent laryngeal nerve compression
- B. Dysphagia due to oesophagus compression.
- C. Superior vena cava syndrome
- D. All of the above

Ques. A 14 years old female patient presents to the ENT OPD complaints that she can understand the language and hears the sound. But unable to understand the meaning. Her Pure tone audiometry and ABR is normal. What is the likely diagnosis in this patient?

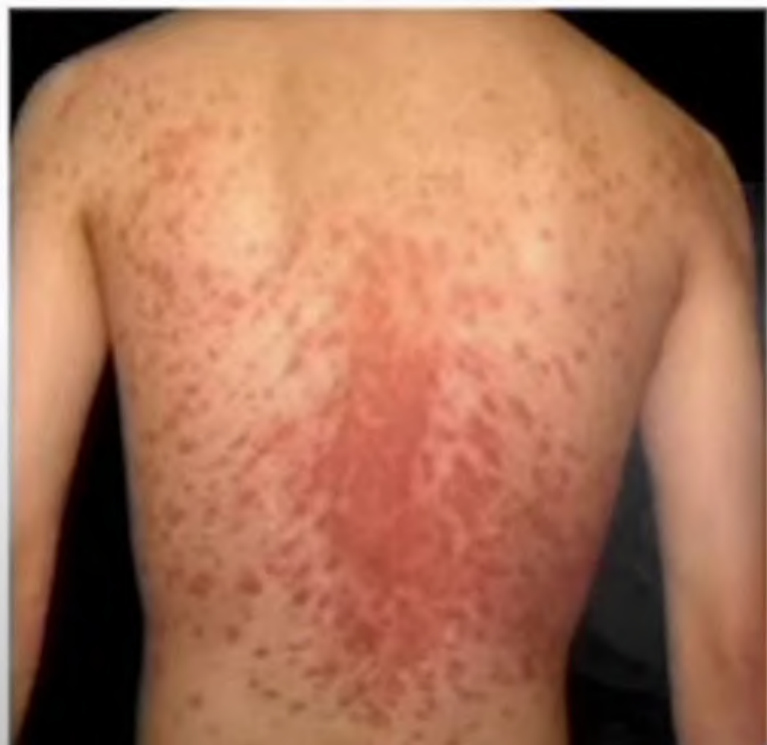- A. Malingering
- B. Wernicke's aphasia/auditory neuropathy
- C. Otosclerosis
- D. Michael aplasia

Dermatology

Ques. Non scarring alopecia is associated with all except ?

- A. Alopecia areata
- B. Androgenetic alopecia
- C. Frontal fibrosing alopecia
- D. Telogen effluvium

Ques. A 24 years old male presents with asymptomatic scaly lesions over the body as shown in the image below. What is the likely diagnosis?



- A. Lichen planus
- B. Pityriasis Rosea
- C. Seborrheic Dermatitis
- D. Atopic Dermatitis

Ques. Statement 1 - A 59 year old patient presents with flaccid blisters. Histopathology shows suprabasal acantholytic split.

Statement 2 - Row of tombstones is diagnostic of Pemphigus vulgaris.

- A. Statement 1 & 2 are correct, 2 is not explaining 1
- B. Statement 1 is incorrect
- C. Statement 1 and 2 is incorrect
- D. Statement 1 and 2 are correct and 2 is the correct explanation for Statement 1.

Ques. A 60 year old female presents with eczematous itching - lesions, Biopsy revealed subepidermal cleft with Direct Immunofluorescence showing Linear C3 & IgG deposition along basement membrane zone. What is the likely diagnosis?

- A. Pemphigus vulgaris
- B. Bullous Pemphigoid
- C. Dermatitis herpetiformis
- D. Pemphigus foliaceus

Ques. Slapped cheek appearance is associated with which of the following ?

- A. Erythema infectiosum
- B. Molluscum contagiosum

- C. Herpes zoster
- D. Kaposi sarcoma

INICET 2023 January session Question Paper (Memory Based)

Question 1. What are the false statement regarding hmp shunt?

- A. utilization of dietary ribose
- B. generation of ribose
- C. generation of acetyl CoA

Question 2. What are Inflammatory cytokines?

Question 3. Damage Control Surgery includes all except?

Question 4. What is Uterine dysfunction?

Question 5. Anion gap increases in?

Question 6. Alkalisation of urine?

Question 7. What is SIRS?

Question 8. What is MTP?

Question 9. In Covid 19 what were the changes in eyes?

Question 10. What is Spherocytosis?