



collegebatch.com

click to campus

NEET PG 2018 Question Paper with Answer

National Eligibility cum Entrance Test (Postgraduate)

Download more NEET PG Previous Year Question Papers: [Click Here](#)

1. Nerves of Branchial arch derived from:

a) Mesoderm

b) Endoderm

c) Neural crest

d) Neuroectoderm

Correct Answer - C

Answer -C. Neural crest

Branchial or pharyngeal arches are masses of mesoderm covered by ectoderm and lined by endoderm. Within these masses, muscular and skeletal components develop, as well as aortic arches and nerve networks. The arches are separated by grooves, visible on the surface of the embryo as pharyngeal clefts and in the interior as the pharyngeal pouches

- In the human embryo, the arches are first seen during the 4th week of development.
- They appear as a series of outpouchings of **mesoderm** on both sides of developing pharynx.
- The **neural crest** are bilaterally paired strips of cells arising in the ectoderm at the margins of the neural tube. These cells migrate to many different locations and differentiate into many cell types within the embryo.

Neural Crest Derivatives

- A key feature of neural crest is the migration into other embryonic tissues to form specific neural and non-neural populations and structures.

Cranial neural crest

- migration - dorsolaterally and into pharyngeal arches
- craniofacial mesenchyme - cartilage, bone, cranial neurons, glia,

- and connective tissues of the face
- pharyngeal arches and pouches - thymic cells, tooth odontoblasts, middle ear bones (ossicles), stria vascularis cells, and jaw (mandible)
- In the body region, neural crest cells also contribute the peripheral nervous system (both neurons and glia) consisting of sensory ganglia (dorsal root ganglia), sympathetic and parasympathetic ganglia and neural plexuses within specific tissues/organs.
- In the head region, neural crest cells migrate into the pharyngeal arches forming ectomesenchyme contributing tissues which in the body region are typically derived from mesoderm (cartilage, bone, and connective tissue).

Neural Crest Origin	
System	Cell Type
Peripheral Nervous System (PNS)	Neurons - sensory ganglia, sympathetic and parasympathetic ganglia, enteric nervous system, and plexuses Neuroglial cells, olfactory ensheathing cells Schwann cells
Endocrine	Adrenal medulla Calcitonin-secreting cells Carotid body type I cells
Integumentary	Epidermal pigment cells
Facial cartilage and bone	Facial and anterior ventral skull cartilage and bones
Sensory	Inner ear, corneal endothelium and stroma
Connective tissue	Tooth papillae smooth muscle, and adipose tissue of skin of head and neck Connective tissue of meninges, salivary, lacrimal, thymus, thyroid, and pituitary glands Connective tissue and smooth muscle in arteries of aortic arch origin

2. Hard palate contains:

- a) Keratinised, submucosa, minor salivary gland
- b) Keratinised, absent submucosal layer, minor salivary gland
- c) Non keratinised, submucosal layer, minor salivary gland
- d) Non keratinised, absent submucosa, minor salivary gland

Correct Answer - A

Answer - A. Keratinised, submucosa, minor salivary gland

The **hard palate** is located on the roof of the oral cavity, posterior and medial to the alveolar process of the maxilla.

The bony structure is formed by the palatine processes of the maxilla and the horizontal plates of the palatine bones.

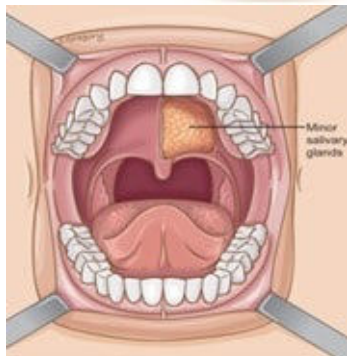
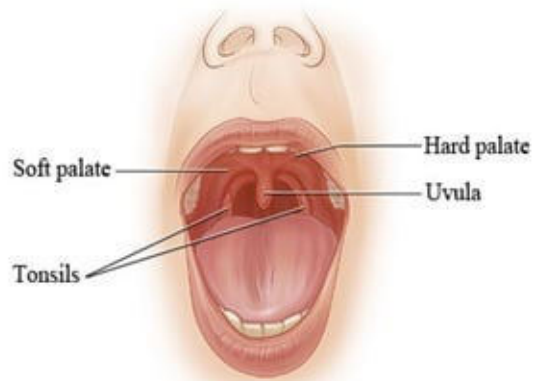
The periosteum is covered by a firmly attached mucosa centrally, although a **submucosa** is apparent laterally containing vessels. The hard palate is continuous with the soft palate posteriorly.

Macroscopic Features

- The hard palate is typically a pale pink colour and may have an orange peel appearance from the **palatine salivary glands** (more common posteriorly).

Microscopic Features

- The hard palate is lined with a **keratinising stratified squamous epithelium**, tightly bound to the underlying periosteum of the palatine bone/maxilla. There is **minimal submucosa**, which becomes more prominent posteriorly.



3. What is the tensor of vocal cords:

a) Cricothyroid

b) Lateral Cricoarytenoid

c) Thyroarytenoids

d) Posterior cricoarytenoids

Correct Answer - A

Answer- A. Cricothyroid

Cricothyroid :	Tensor of vocal cords.
Lateral cricoarytenoid:	Abductor of vocal cords.
Thyroarytenoid:	Relaxor of vocal cords.
Posterior cricoarytenoid:	Abductor of vocal cords

Muscles acting on the Larynx

Movement

Muscles

Elevation of Larynx Thyrohyoid, mylohyoid

Depression of larynx Sternothyroid, sternohyoid

Opening inlet of larynx Thyroepiglotticus

Closing inlet of larynx Aryepiglotticus

Abductor of vocal cords

Posterior cricoarytenoid only

Adductor of vocal cords

Lateral cricoarytenoid transverse & oblique arytenoids

Tensor of vocal

cords

Cricothyroid

**Relaxer of vocal
cords**

Thyroarytenoid

4. Ureteric bud develops from:

a) Mesonephros

b) Metanephros

c) Pronephros

d) Genital sinus

Correct Answer - A

Answer- A. Mesonephros

The **ureteric bud**, also known as the **metanephrogenic diverticulum**, is a protrusion from the mesonephric duct during the development of the urinary and reproductive organs.

It later develops into a conduit (channel) for urine drainage from the kidneys, which, in contrast, originate from the **metanephric blastema**.

The **metanephrogenic blastema** or metanephric **blastema** (or metanephric mesenchyme, or metanephric mesoderm) is one of the two embryological structures that give rise to the kidney, the other being the ureteric bud.

5. About Weber's syndrome which is incorrect:

- a) Contralateral hemiplegia
- b) Ipsilateral Oculomotor nerve palsy
- c) Contralateral Parkinsonism
- d) Anterior cerebral peduncle

Correct Answer - D

Answer - D. Anterior cerebral peduncle

Weber's syndrome (superior alternating hemiplegia) is a form of **stroke** characterized by the presence of an ipsilateral **oculomotor nerve palsy** and contralateral **hemiparesis** or **hemiplegia**.

It is caused by **midbrain infarction** as a result of occlusion of the **paramedian branches** of the **posterior cerebral artery** or basilar bifurcation perforating arteries.

This lesion is usually unilateral and affects several structures in the midbrain:

- **Contralateral parkinsonism** because its dopaminergic projections to the basal ganglia innervate the ipsilateral hemisphere motor field, leading to a movement disorder of the contralateral body.
- **Contralateral hemiparesis** and typical upper motor neuron findings. It is contralateral because it occurs before the decussation in the medulla.
- Difficulty with contralateral lower facial muscles and hypoglossal nerve functions.
- **Ipsilateral Oculomotor nerve palsy** with a drooping eyelid and fixed wide pupil pointed down and out. This leads to diplopia.

6. About Sibson's fascia which is incorrect:

- a) Attached to the inner border of 2nd rib
- b) Covers apical part of lung
- c) Part of scalenus anterior muscle
- d) Vessel pass above the fascia

Correct Answer - A

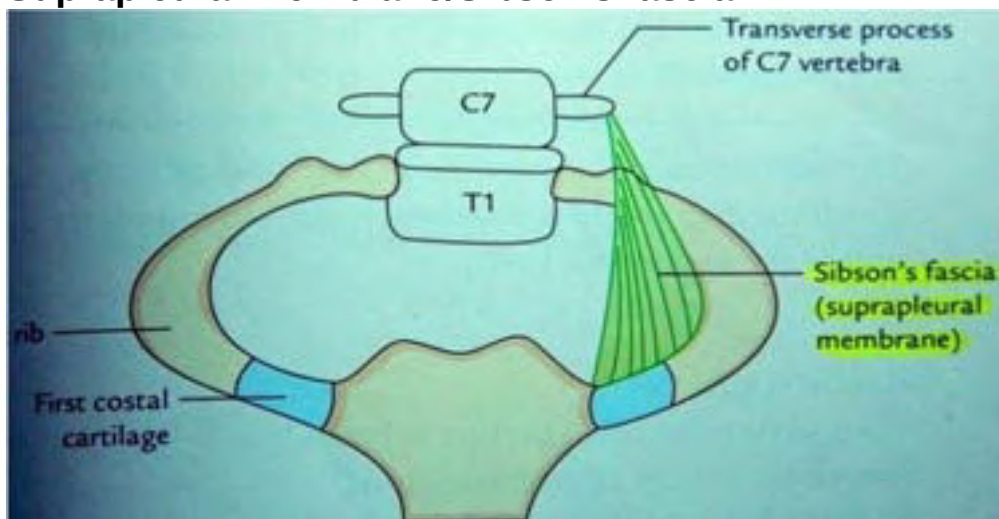
Answer-A. Attached to the inner border of 2nd rib

The **suprapleural membrane** is known as **Sibson's fascia**.

It refers to a thickening of connective tissue that covers the apex of each human lung.

It attaches to the **internal border of the first rib** and the transverse processes of **vertebra C7**.

Suprapleural membrane/Sibson's fascia



7. Thrombosis of posterior inferior cerebellar artery causes:

a) Lateral medullary syndrome

b) Weber syndrome

c) Medial medullary syndrome

d) none

Correct Answer - A

Answer- A. Lateral medullary syndrome

The **posterior inferior cerebellar artery (PICA)**, the largest branch of the vertebral artery, is one of the three main arterial blood supplies for the cerebellum, part of the brain.

Occlusion of the posterior inferior cerebellar artery or one of its branches, or of the vertebral artery leads to **lateral medullary syndrome** also called **Wallenberg syndrome**

8. Broca's area situated in:

- a) Inferior frontal gyrus
- b) Superior temporal gyrus
- c) Angular gyrus
- d) None of the above

Correct Answer - A

Answer- A. Inferior frontal gyrus

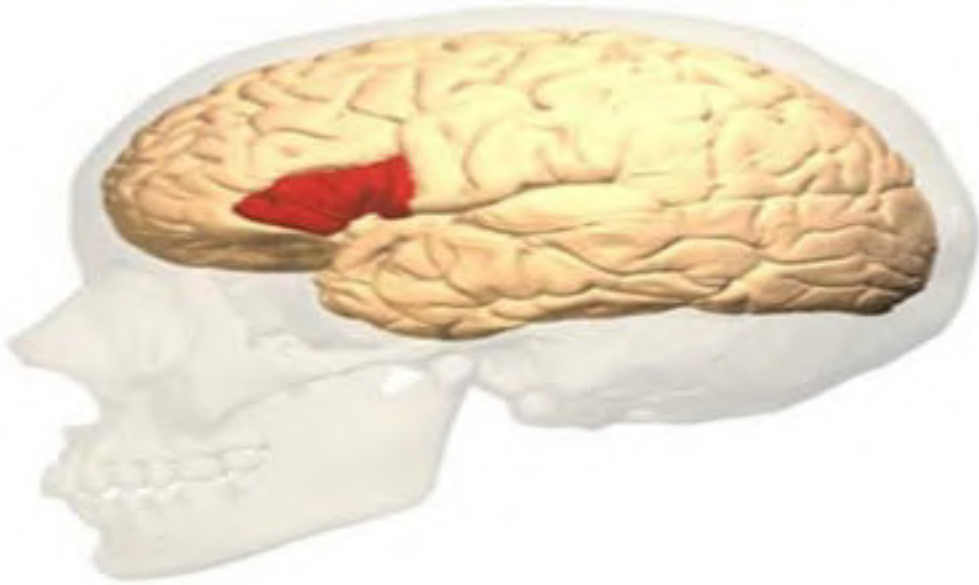Broca's area or the **Broca area (44)** is a region in the frontal lobe of the dominant hemisphere (usually the left) of the hominid brain with functions linked to speech production.

Inability to speak after injury to the posterior **inferior frontal gyrus** of the brain.

Pierre Paul Broca identified this region, known as Broca's area.

Difficulty in language production as **Broca's aphasia**, also called **expressive aphasia**.

Broca's area is now typically defined in terms of the **pars opercularis** and **pars triangularis** of the inferior frontal gyrus.



BROCA'S AREA(shown in red). Colored region is pars opercularis and pars triangularis of the inferior frontal gyrus. Broca's area is now typically defined in terms of the pars opercularis and pars triangularis of the inferior frontal gyrus.

9. Acute tonsillitis effects which nerve:

a) Glossopharyngeal Nerve

b) Facial Nerve

c) Trigeminal nerve

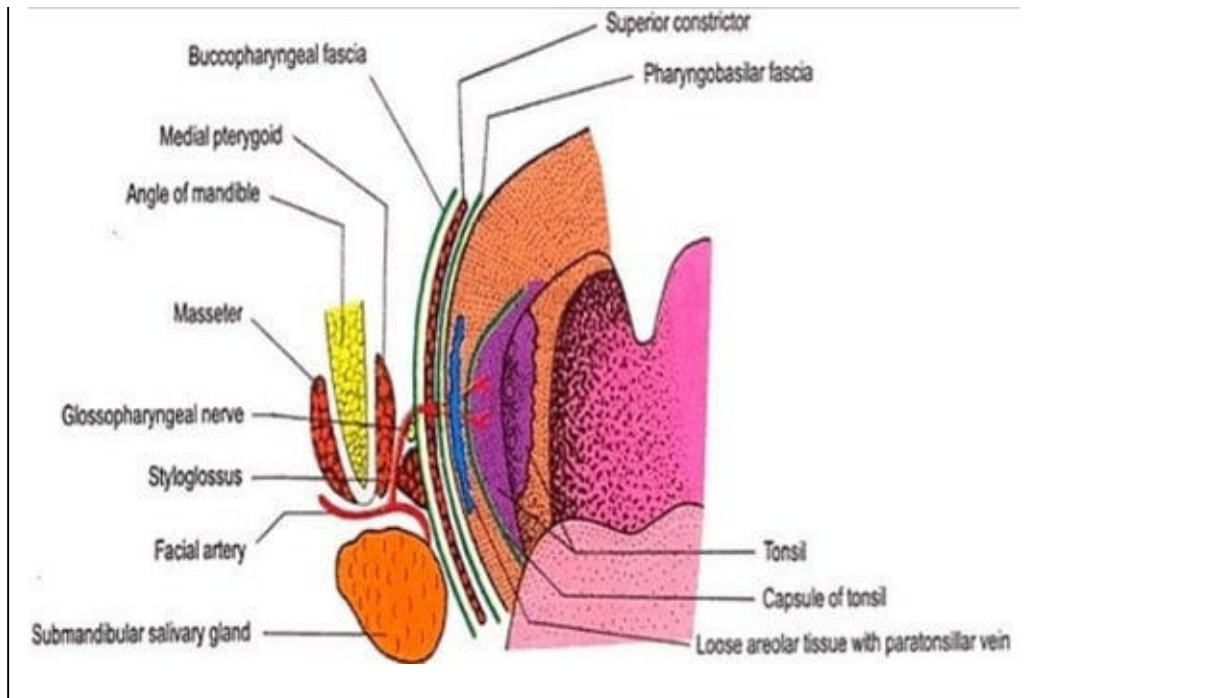
d) Vagus Nerve

Correct Answer - A

Answer- A. Glossopharyngeal Nerve

The nerves supplying the palatine tonsils come from the maxillary division of the trigeminal nerve via the lesser palatine nerves, and the tonsillar branches of the glossopharyngeal nerve. The glossopharyngeal nerve continues past the palatine tonsil and innervates the posterior 1/3 of the tongue to provide general and taste sensation. This nerve is most likely to be damaged during a tonsillectomy, which leads to reduced or lost general sensation and taste sensation to the posterior third of the tongue.

Relations of tonsillar bed



10. Structures not passing through Aortic opening:

a) Azygos vein

b) Aorta

c) Thoracic duct

d) Vagus

Correct Answer - D

Answer - D. Vagus

Aortic opening (**Aortic hiatus**) is one of the three major apertures through the diaphragm & lies at the level of T12.

Several structures pass through the aortic hiatus: **aorta, azygos vein, thoracic duct.**

Vagus passes through **the oesophageal hiatus.**

11. What should be the value of BMI to be considered as “Lethal” in men?

a) 12

b) 18

c) 13

d) 14

Correct Answer - C

Answer: C – 13

BMI Value of 13 is considered as “Lethal” in men.

- Body mass index (BMI) is an estimate of total body fat mass
- Simply an index of weight for height.

Formula:

- Weight in kilograms divided by the square of height in meters.
- Body mass index = $\text{Weight (kg)} / (\text{Height (m)})^2$

Uses:

- Used to classify and define underweight, overweight & obesity in adults.

Classification & Metrics:

- World Health organization categorized BMI values into:

Classification	BMI value
Normal weight	18.5 to 24.9 kg/m ²
Underweight	<18.5
Pre-obesity (Pre-OB)	25 to 29.9 kg/m ²
Obesity (OB)	> 30 kg/m ²
Class I obesity	30.0 - 34.9 kg/m ²
Class II obesity	

Class III obesity (Morbid form)	35.0 - 39.9 kg/m ² More than 40 kg/m ²
---------------------------------	---

BMI value considered lethal for Men is 13

Females withstand and survive even at lower BMI rate up to 11.

12. Which receptors are blocked in Myasthenia Gravis?

a) Ach receptors

b) Ca^{++} receptors

c) Na^{2+} receptors

d) Opioid receptors

Correct Answer - A

Answer: A - Ach receptors

An autoimmune disease

Antibody mediated autoimmune attack of acetylcholine receptors.

Inability of neuromuscular junctions to transmit signals from nerve to muscle

Resulting in muscle weakness and fatigability.

Unresponsive respiratory muscles may cause respiratory failure in severe cases.

Analysis of neuromuscular transmission reveal

- Decrease in acetylcholine receptors (AChRs)
- Loss of post-junctional folds.
- Circulating antibodies to acetylcholine receptors positive.

Diagnosis:

- **Clinical test:** Strength improvement in response to administration of anticholinesterase agents.

Treatment:

- **Anti-cholinesterase drugs:** Allows accumulation of larger amounts of acetylcholine in synaptic junctions.
- Neostigmine.

13. What is the characteristic pattern seen in Brown sequard syndrome -

- a) C/L loss of joint sense and position
- b) C/L loss of pain
- c) I/L loss of complete sensory functions
- d) C/L motor functions

Correct Answer - B

Answer: B - Contralateral loss of pain sensations

If the spinal cord is completely transected – All the sensations and motor functions distal to segment of transection are blocked.

Transection of spinal cord on single side results in “Brown Sequard Syndrome”

Functions affected:

Function affected	Position	Description
Motor	Ipsilateral side	Complete loss of motor functions below the level of transection
Sensory	Combined effects observed	Some sensory functions are lost on transected side and others on opposite side.
	On the Contralateral side: Sensation of pain, cold, & heat	Result of disturbance in Spinothalamic pathway. Loss observed 2 to 6 segments below the level of transection.
	Discrete Crude touch	Poorly localized (Still persists).

	Partial transmission occurs in opposite Spinothalamic tract
--	--

14. When V_a / Q is infinity?

- a) Partial pressure of O_2 becomes zero
- b) No exchange of O_2 & CO_2
- c) Partial pressure of CO_2 alone becomes zero
- d) Partial pressure both CO_2 and O_2 remain normal

Correct Answer - B

Answer: B - No exchange of O_2 & CO_2

- V_a represents the ventilation in alveoli.
- Q represents the blood flow through the alveolus.
- The ratio of V_a and Q explains the respiratory exchange when there is an imbalance between alveolar ventilation and alveolar blood flow. The ventilation-perfusion ratio is considered normal there is an equal amount of blood flow & ventilation through alveolus.
- V_a / q ratio is Zero -
 - There is inadequate or nil, but perfusion persists
- **V_a / q ratio is infinity -**
 - **There is adequate ventilation but no perfusion.**
- Both in the Zero and infinity V_a / Q ratio, there is no exchange of gases through the respiratory membranes of corresponding alveoli.
- **When V_a / Q ratio is infinity,**
 - The alveolar air equilibrates the humidified inspired air
 - No exchange of oxygen and carbon-di-oxide occurs.
 - Partial pressures of the O_2 and CO_2 are 149mmHg & 0 mmHg respectively

15. C wave is seen in -

a) Iso -volumetric contraction

b) Slow filling at end of diastole

c) End of systole

d) Start of diastole

Correct Answer - A

Ans. A. Iso -volumetric contraction

C wave:

- Produced by bulging of tricuspid valve into right atrium during Iso-volumetric contraction of right ventricle.

16. Alpha waves are seen during?

a) Sleep

b) REM movements

c) Relaxed state

d) Active state

Correct Answer - C

Answer: C - Relaxed state

- Regarded as normal wavefront
- Occur **when at rest and eyes closed with active/wandering mind**
 - ie., associated with a **decreased level of attention (either during relaxed/subconscious thinking)**
- Regular Rhythm (Frequency 8-13 Hz Amplitude - 50-100 V)

17. In hypovolemic shock there is -

a) Afferent arteriolar constriction

b) Efferent arteriolar constriction

c) Increased blood flow to kidney

d) Normal cardiac output

Correct Answer - A

Answer: A. Afferent arteriole constriction

Inadequate circulation volume.

Poor venous return to heart will decrease the stroke volume & cardiac output.

Compensation by tachycardia & increased systemic vascular resistance (SVR).

Become cold peripherally (shut down).

Most common causes - Fluid loss of any etiology

Hemorrhage

Salt & water loss

Sepsis

Burns

18. Components responsible for counter current mechanism in kidney are all except:

- a) Sodium outflow in thick ascending limb
- b) Water outflow in thin descending limb
- c) Sodium outflow in thin ascending limb
- d) Flow of tubular fluid from PCT to DCT

Correct Answer - C

Answer: C. Sodium outflow in thin ascending limb

Counter-current system occurs in kidney

A system in which inflow runs parallel to, counter to, and in close proximity to the outflow for some distance.

2 countercurrent mechanisms available:

- Countercurrent multiplier at Loop of Henle
- Generate high medullary osmotic gradient pressure
- Countercurrent exchanger at vasa recta of medullary capillaries
- Helps in maintain the medullary osmotic pressure gradient

Substances involved in countercurrent mechanism include:

- Sodium actively absorbed with co-transport of potassium & chlorine in thick ascending limb of loop of Henle.
- Water reabsorbed in thin descending limb of loop of Henle.
- Urea diffuse out from the medullary collecting ducts into medullary interstitium.

19. Glucose is absorbed in intestine by?

a) Secondary active transport

b) Facilitated diffusion

c) Simple diffusion

d) Primary active transport

Correct Answer - B

Answer: B. Facilitated diffusion

Facilitated diffusion is a diffusion of large water soluble molecule by a carrier protein.

Glucose and amino acids are transported across the membrane by this method.

20. Insulin like growth factor is secreted by:

a) Liver

b) Pituitary gland

c) Pancreas

d) Adrenal glands

Correct Answer - A

Answer: A. Liver

- Growth hormone **acts on the liver** to form small proteins called “Somatomedins”
- Somatomedins increases bone growth in all aspect
- **Effects are similar to insulin, hence referred to as “Insulin-like Growth Factor” (IGF).**
- **Four types available -**
- Most important is Somatomedin C - Specifically referred to as “Insulin - Growth Factor -1 / IGF - 1”
- Binds to a carrier protein in blood
- Hence, a longer duration of action than growth hormone.
- Half-life - about 20 Hrs (compared to growth hormone - 20 mins)
- Blood concentration of IGF-1 follows the levels of growth hormone.
- Growth effects of GH are mostly attributed to somatomedin (rather than its direct effect on bones & peripheral tissues)

21. What is Prosopagnosia?

- a) Impairment of consciousness
- b) Being unaware of one's problems
- c) Difficulty in identifying known faces
- d) Failure to identify objects

Correct Answer - C

Ans. C. Difficulty in identifying known faces.

- A feature of anxiety disorder
- **Prosopagnosia is difficulty in identifying known faces**
- Other features of anxiety disorder include,
- Memory impairment without impairment of consciousness
- Being unaware of one's problem (Agnosognosia)

22. Tyrosinosis is caused due to deficiency of which enzyme?

- a) Fumarylacetoacetate hydrolase.
- b) p-hydroxy phenylpyruvate dehydrogenase.
- c) Tyrosine transaminase.
- d) Tyrosine ligase.

Correct Answer - A

Answer: A. Fumarylacetoacetate hydrolase

- Several metabolic disorders are associated with the tyrosine catabolic pathway. The probable metabolic defect in type I tyrosinemia (tyrosinosis) is at fumarylacetoacetate hydrolase.
- It is characterized by buildup of too much of the amino acid tyrosine in the blood and tissues due to an inability to metabolize it
- The therapy employs a diet low in tyrosine and phenylalanine. Untreated acute and chronic tyrosinosis leads to death from liver failure.

23. Lesch–Nyhan syndrome is caused by deficiency of which enzyme?

- a) Orotate Phosphoribosyltransferase
- b) Uracil phosphoribosyltransferase
- c) Quinolinate Phosphoribosyltransferase
- d) Hypoxanthine-guanine phosphoribosyltransferase (HGPRT)

Correct Answer - D

Answer: D. Hypoxanthine-guanine phosphoribosyltransferase (HGPRT)

- The condition is called Lesch-Nyhan syndrome, in which there is complete deficiency of HGPRT.
- HGPRT deficiency causes decreased utilization of PRPP in salvage pathway.
- This results in increased production of purine nucleotide from PRPP via de-novo pathway.
- The disease is characterized by hyperuricemia, gouty arthritis, urinary stones, neurological symptoms.

24. Fish odor syndrome is caused by deficiency of which enzyme?

a) Fumarylacetoacetate hydrolase

b) Methane monooxygenase

c) Monooxygenase 3 (FMO3)

d) D-amino acid oxidase

Correct Answer - C

Answer: C. Monooxygenase 3 (FMO3)

Trimethylaminuria, or fish odor syndrome (FOS), is a condition characterized by the presence of trimethylamine (TMA)—a tertiary amine whose odor is described as resembling that of rotting fish—in the urine, sweat, and expired air. The cause of the syndrome is rooted in the dysfunctional metabolism of TMA, which is normally oxidized by flavin monooxygenase 3 (FMO3) into non-odorous trimethylamine-N-oxide (TMAO).

Most patients with FOS are eventually diagnosed with primary trimethylaminuria, which is caused by a deficiency in FMO3 that is inherited in an autosomal recessive fashion.

The diagnosis is made on the basis of the clinical presentation and urinalysis. Urine can be analyzed for the concentration of both TMA and TMAO, and the results may be given as an oxidizing ratio based on the formula- $\text{TMAO}/(\text{TMAO}+\text{TMA}) \times 100\%$.

Short courses of oral neomycin, metronidazole, and amoxicillin have been reported to be useful in some cases.

25. Galactosemia is due to deficiency of which enzymes

a) Galactose-1-phosphate uridylyltransferase

b) HGPRT

c) Galactokinase

d) Epimerase

Correct Answer - A

Answer: A. Galactose-1-phosphate uridylyltransferase

Galactosaemia (British galactosaemia) is a rare genetic metabolic disorder that affects an individual's ability to metabolize the sugar galactose properly. Galactosemia follows an autosomal recessive mode of inheritance that confers a deficiency in an enzyme responsible for adequate galactose degradation.

26. Which of the following is most abundant end product of fatty acid synthesis -

a) Oleic acid

b) Palmitic acid

c) Arachidonic acid

d) Glucose

Correct Answer - B

Answer: B. Palmitic acid

Fatty acid are synthesized by extramitochondrial system.

This system is present in many tissues including liver kidney brain lung mammary gland and adipose tissues.

Acetyl CoA is immediate substrate.

The end products of this synthesis are usually the saturated fatty acids palmitate and stearate with the latter predominating.

27. About DNA polymerase I which one is correct?

- a) Not required in bacteria
- b) Repair any damage with DNA
- c) Involved in okazaki fragment
- d) Participate in DNA replication

Correct Answer - A

Answer: A. Not required in bacteria

DNA polymerase I participates in the DNA replication of prokaryotes. Function of Pol I is mainly to repair any damage with DNA, but it also serves to connect okazaki fragments deleting RNA primers and replacing the strand with DNA.

28. What does chaperones assist in?

a) Protein Cleavage

b) Protein Folding

c) Protein Degradation

d) Protein Modification

Correct Answer - B

Answer: B. Protein Folding

Folding of Proteins in Vivo Is Promoted by Chaperones

29. Fishy odour occurs due to deficiency of this vitamin from diet -

a) Biotin

b) Thiamine

c) Riboflavin

d) Vit. A

Correct Answer - C

Answer: C. Riboflavin

Vitamin B2 or riboflavin **deficiency** can bring about a **fishy odor** in the body.

* Fish-odor syndrome, also called **trimethylaminuria**, is a rare metabolic disorder caused by the absence of enzyme n-oxidase (A Flavin containing monooxygenase, 3(FMO3). Gene for trimethylamine c has been mapped on chromosome 1(lq23-q25).

* Trimethylamine is normally produced in the intestine from the breakdown of dietary choline and trimethylamine oxide by bacteria.

* Egg yolk and liver are the main sources of choline, and fish is the major source of **trimethylamine oxide**.

* Trimethylamine is absorbed and oxidized in the liver by trimethylamine oxidase (flavin-containing monooxygenases) to trimethylamine oxide, which is odorless and excreted in the urine. Deficiency of the enzyme results in massive excretion of trimethylamine in urine.

* Consequently, to these patients such foods may taste like rotten fish and impart a fishy odor to their saliva, sweat and urine.

Treatment

* Restriction of fish, eggs, liver and other sources of choline

(such as nuts and grains) in the diet significantly reduce the odor.

- Treatment with short course of oral metronidazole, neomycin or lactulose causes temporary reduction in the body odor.

- * Riboflavin supplement can be given to enhance residual FMO3 activity.

30. VMA is excreted in urine in which condition -

a) Alkaptonuria

b) Phenylketonuria

c) Pheochromocytoma

d) Diabetic ketoacidosis

Correct Answer - C

Answer: C. Pheochromocytoma

VMA is the end product of catabolism of catecholamines.

In pheochromocytoma and neuroblastoma there is excessive synthesis of catecholamines which causes enhanced synthesis of VMA and its excretion in the urine.

VMA is the urinary product of both epinephrine and norepinephrine. It is a good screening test for pheochromocytoma, and is also used to diagnose and follow up neuroblastoma and ganglioneuroma.

31. In Cystinuria all of the following amino-acids reabsorption defect is present, except

a) Lysine

b) Citrulline

c) Arginine

d) Ornithine

Correct Answer - B

Ans. is 'B' i.e., Citrulline

Types of cystinuria

* Type-I: It is homozygous with a fully recessive form. The patient excretes a large quantity of cystine, ornithine, lysine, and arginine. Gene involved is rBAT on chromosome-2.

* Type-II & III: These are heterozygous variants of incompletely recessive forms. They excrete cystine, ornithine, lysine, and arginine more than normal but less than the homozygous state (Type-I). Gene involved is SLC7A9 on chromosome 79.

Cystinuria

* **Biochemical Defect:** An autosomal recessive disorder that results in the formation of a defective amino acid transporter in the renal tubule and intestinal epithelial cells.

* **Pathophysiology:** The amino acid transporter is responsible for transporting cystine, ornithine, lysine, and arginine. Defective tubular reabsorption of these amino acids in the kidneys results in increased cystine in the urine, which can precipitate and cause kidney stones.

* **Clinical Manifestations:** Cystine kidney stones presenting with

severe, intermittent flank pain and hematuria.

* **Lab findings:** Increased urinary excretion of cystine, ornithine, arginine, and lysine on urine amino acid chromatography; hematuria and cystine crystals (hexagonal) on the cooling of acidified urine sediment.

* **Imaging:** Radiopaque kidney stones on CT scan. The most specific test is the cyanide–nitroprusside test

* **Treatment:** Low-methionine diet; increased fluid intake; acetazolamide to alkalinize the urine. If this fails then patients are usually started on chelating therapy with penicillamine.

32. Fibrinopeptide A and fibrinopeptide B are acidic due to the presence of which amino acids in its structure -

a) Serine and threonine

b) Glutamate and aspartate

c) Histidine and lysine

d) Glutamine and valine

Correct Answer - B

Answer: B. Glutamate and aspartate

The N-terminal A and B portions of the A α and B β chains are termed fibrinopeptide A (FPA) and fibrinopeptide B (FPB), respectively.

These domains are highly negatively charged as a result of an abundance of aspartate and glutamate residues.

The negative charges contribute to the solubility of fibrinogen in plasma and importantly also serve to prevent aggregation by causing electrostatic repulsion between fibrinogen molecules.

33. HIAA in urine present in?

a) Alkaptonuria

b) Albinism

c) Carcinoid

d) Phenylketonuria

Correct Answer - C

Answer: C. Carcinoid

Carcinoid syndrome develops in some people with carcinoid tumors and is characterized by cutaneous flushing, abdominal cramps, and diarrhea.

Carcinoid tumour occur throughout the gastrointestinal tract, most commonly in the appendix, ileum and rectum in decreasing order of frequency.

Right-sided valvular heart disease may develop after several years. The syndrome results from vasoactive substances (including serotonin, bradykinin, histamine, prostaglandins, polypeptide hormones) secreted by the tumor, which is typically a metastatic intestinal carcinoid.

Diagnosis is clinical and by demonstrating increased urinary 5-hydroxyindoleacetic acid(HIAA).

Tumor localization may require a radionuclide scan or laparotomy. Treatment of symptoms is with somatostatin or octreotide, but surgical removal is performed where possible; chemotherapy may be used for malignant tumors.

34. Warthin finkeldey cells are seen in

a) Measles

b) Rubella

c) Rabies

d) Typhoid

Correct Answer - A

Answer: A. Measles

Multinucleated cells like Warthin Finkeldey are seen in Measles

- Measles virus infects by invasion of respiratory epithelium.
 - Local multiplication leads to viremia (day 2-3), then spread to RE system.
 - Two types of Multinucleated giant cells in both epidermis & oral epithelium by 7-11 days.
 - **Warthin Finkeldey cells of reticuloendothelial system**
 - Epithelial giant cells of respiratory & other epithelia.
- Warthin–Finkeldey cell:**
- Type of giant multinucleate cell found in hyperplastic lymph nodes early in the course of measles
 - Under the light microscope, these cells consist of a large, grape-like cluster of nuclei.
 - Also with HIV-infected individuals and Kimura disease .
 - Rarely in neoplastic (e.g. lymphoma) & non-neoplastic lymph node disorders.
 - Unknown origin; Reports of staining with markers similar to follicular dendritic cells, including CD21.

35. CD59 marker of which disease

a) PNH

b) PTEN

c) BRR

d) Cowden syndrome

Correct Answer - A

Answer: A. Paroxysmal nocturnal hemoglobinuria (PNH)

Paroxysmal nocturnal hemoglobinuria (PNH) is a disease, due to acquired **mutations** in “**Phosphatidylinositol GlycanComplementation Group A**” gene (**PIGA**)..

Associated with **deficiency of glycosylphosphatidylinositol (GPI)** anchor proteins along with absence of external surface membrane proteins attaching to it.

CD55 (DAF) and CD59 (MIRL) are two such complement defence proteins

CD59 deficiency:

- **Common finding in RBCs & WBCs of patients with chronic hemolysis suffering from PNH**

Diagnosis:

- The definite diagnosis based on demonstration of a substantial proportion of patient's RBC having increased susceptibility to complement (C), due to the deficiency on their surface of proteins (particularly CD59 & CD55)

36. Opsonin is

a) C3a

b) C3b

c) C5a

d) C6

Correct Answer - B

Answer: B. C3b

The process of coating a foreign particle targeting & preparing it for phagocytosis process is "Opsonization". Substances involved are opsonins.

Main opsonins from complement system is C3

Examples of opsonins include:

Antibodies:

- IgG and IgA

Components of the complement system:

- C3b, C4b, and iC3b

Mannose Binding Lectin (MBL):

- Initiates the formation of C3b
- Membrane Attack Complex (MAC)
- Includes C5b, C6, C7, C8 & polymeric C9

Opsonization & complement proteins:

- Mainly C3b, iC3b & C4b

C3:

- Most abundant protein of all complementary proteins,
- Cleaves into C3a and C3b

C3a -

- Binds and activates mast cells & basophils, release histamine.

C3b -

- Most critical component in both classical & alternative pathway
- C3b attaches to bacterial surfaces for opsonization by phagocytes

37. Bernard–Soulier syndrome due to deficiency of

a) Gp 2b/3a

b) Gp 1b

c) vWf

d) TNF

Correct Answer - B

Answer: B. Gp 1b

Bernard–Soulier syndrome (BSS) / Hemorrhagic Parous
Thrombocytic Dystrophy

Rare autosomal recessive coagulopathy

Causes a deficiency of glycoprotein 1b (Gp1b), receptor for von Willebrand factor.

38. Cowden syndrome

a) P53

b) PTEN

c) Rb

d) Ras

Correct Answer - B

Answer: B. PTEN

“Phosphatase and Tensin” homolog (PTEN)- protein in humans encoded by the **PTEN** gene. Gene mutations promotes development of cancers.

Cowden’s disease / Multiple Hamartoma Syndrome -

- Part of PTEN hamartoma tumor syndrome
- An autosomal dominant syndrome
- Trichilemmomas - Numerous tumors of hair follicles in face
- Multiple hamartomatous polyps in GI tract.
- Very high risk of breast & thyroid carcinoma

Treatment:

- B/L mastectomies recommended
- Contraindicated are mammography & other radiation exposure of breast tissue

39. Chromosome involved in myotonic dystrophy is

a) Chromosome 19

b) Chromosome 20

c) Chromosome 21

d) Chromosome 22

Correct Answer - A

Answer: A - Chromosome 19

Myotonic dystrophy is transmitted by mutation in an 'unstable trinucleotide repeat sequence' in **gene 19q 133**.

Features:

- An autosomal dominant disorder
- Most common adult muscular dystrophy

Characteristics feature:

- **Myopathy is distal** (in contrast to other myopathies - mostly proximal).
- Muscle atrophy selectively **involves type I fibres only**
- Appears by **5 years**, causes **a slow relaxation of hand grip** following a **forced voluntary closure**.

40. TRALI occurs within how many hours of transfusion?

a) 48 Hrs

b) 72 Hrs

c) 6 Hrs

d) 12 Hrs

Correct Answer - C

Answer: C - 6 Hrs

Transfusion-Related Acute Lung Injury (TRALI) - Syndrome characterized by **acute respiratory distress following transfusion**.

Symptoms:

- Typically develop **during, or within 6 hours of transfusion**.
- **Rapid onset of dyspnea & tachypnea**.
- Associated fever, cyanosis, & hypotension.

Clinical examination:

- Reveals **respiratory distress**.
- **Pulmonary crackles** may be present with no signs of CHF or volume overload.
- CXR - Evidence of B/L pulmonary edema unrelated to CHF (**non-cardiogenic pulmonary edema**),
- Bilateral patchy infiltrates rapidly progressing to **complete "white out"** indistinguishable from Acute Respiratory Distress Syndrome (ARDS).

41. Kidney responds to shock by

- a) Decreases renal blood flow
- b) Increases afferent arteriole resistance
- c) GFR remains unaltered
- d) Perfusion of kidney increases

Correct Answer - B

Answer: B - Increases afferent arteriole resistance

Kidney utilizes the following mechanisms as a response to shock:

- **Release of aldosterone** from hypoxic kidney
- **Release of ADH** due to decreased effective circulating blood volume.
- **Reduced GFR** due to **arteriole constriction**
- Tissue fluid shift into plasma due to lowered hydrostatic pressure (Hypotension)

42. Which of the following is epithelial tumor of stomach?

a) Carcinoid

b) Lymphoma

c) GIST

d) Gastric adenocarcinoma

Correct Answer - D

Answer: D - Gastric adenocarcinoma

Malignant epithelial tumor originating from glandular epithelium of gastric mucosa.

Aggressively invade the gastric wall.

Lauren classification:

- Two types of gastric adenocarcinoma are present.
- Intestinal type
- Diffuse type
- Intestinal type - Irregular tubular structures
- Diffuse type - Mucinous & colloidal "Leather-bottle stomach"

43. Identify an X linked disorder?

a) Color blindness

b) Thalassemia

c) Azoospermia

d) Retinitis Pigmentosa

Correct Answer - A

Answer: A - Color blindness

Hereditary color blindness/ Achromatopsia

The ability to appreciate one or more primary color is defective (**anomalous**) or absent (anopia)

Due to mutations in X chromosome

Red & green pigment cones coded by X chromosome; Blue coded on chromosome 7

More common in males than females

Acquired - (Optic nerve/ macular damage)

Ishihara chart -

- **Test red/ green color blindness - Farnsworth 100 hue test**

Other s:

- Azoospermia&Retinitis Pigmentosa - Y-chromosome linked disorder
- Thalassemia - Inherited (Autosomal recessive pattern) blood disorders characterized by abnormal hemoglobin production. Genes in Chromosome 11 and 16 involved.

44. H And L variety seen in

a) Mixed cellularity hodgkin

b) Lymphocyte depleted

c) Lymphocyte predominance

d) Nodular sclerosis

Correct Answer - C

Answer: C - Lymphocyte predominance

Hodgkin lymphoma (HL) - common “Malignant Lymphomas”

2 entities:

- Classical HL (cHL)
- Nodular Lymphocyte–predominant HL (NLPHL).

Cells :

- Classical HL - Hodgkin and Reed/Sternberg (HRS) cells
- Nodular Lymphocyte predominant HL - Lymphocytic & Histiocytic (L&H) cells

45. Stellate granuloma seen in

a) Sarcoidosis

b) Cat scratch disease

c) Cryptococcosis

d) Histoplasmosis

Correct Answer - B

Answer: B - Cat scratch disease

Bacterial infection caused by *Bartonella henselae*

Acquired infected cat/kitten scratch

Histology:

- Characterized by granulomatous inflammation of lymph nodes.
- Skin lesion demonstrates a circumscribed focus of necrosis
- Regional lymph nodes demonstrate **follicular hyperplasia with central stellate necrosis** with neutrophils, surrounded by palisading histiocytes (suppurative granulomas) & sinuses packed with monocytoïd B cells, usually without perifollicular and intrafollicular epithelioid cells.

46. Which best explains “Flipping effect”?

a) LDH 1 > LDH 2

b) LDH2 > LDH1

c) LDH 2 > LDH 3

d) LDH 3 > LDH 2

Correct Answer - A

Answer: A - LDH 1 > LDH 2

Lactate dehydrogenase, tetrameric enzyme with 4 subunits, 4 Subunits with 2 isoforms - **H isoform (Heart) & M isoform (Muscle)**

Heart & RBCs - LDH-1 (4H);

- Reticuloendothelial system - LDH-2 (3H1M)
- Lungs - LDH-3 (2H2M)
- Kidneys, placenta, & pancreas - LDH-4 (1H3M)
- Liver & striated muscle - LDH-5 (4M)

Uses:

- LDH levels are more in RBC
- Helpful in assessment of Hemolysis / Tissue breakdown

Flipping effect:

- Usually LDH 2 is predominant in serum & LDH 1 is predominant in heart
- Higher levels of LDH 1 than LDH 2 (Flipped pattern) is suggestive of myocardial infarction
- Damaged cardiac tissues release LDH 1 into bloodstream.

47. Nude mice is not resistant to xenograft due to absence of

a) B cell

b) T cell

c) Both b and t cell

d) None

Correct Answer - B

Answer: B - T cell

Nude mice lacks "Thymus" & cannot generate mature T lymphocytes.

Absence of T-lymphocytes makes it **unable to mount adaptive immune responses** requiring CD4, helper T cells, CD8 and cytotoxic T cells.

Adaptive immune responses that remain unresponsive to nude mice include:

- Antibody formation (CD4 + helper T cells)
- Cell-mediated immune responses (CD4+ and/or CD8+ T cells)
- Delayed-type hypersensitivity responses (CD4+ T cells)
- Killing of virus-infected or malignant cells (CD8 + cytotoxic T cells)
- Graft rejection (both CD4+ & CD8+ T cells)

Uses:

- Laboratory study animal - Insights into immune system, leukemia, solid tumors, AIDS & other immune deficiency diseases.
- Absence of functioning T cells prevents them rejecting the allografts & Xenografts.

48. Anaplasia is

- a) Changing one type of epithelium to another
- b) Nuclear chromatin
- c) Lack of differentiation
- d) Morphological changes

Correct Answer - C

Answer: C - Lack of differentiation

Refers to a lack of differentiation in neoplastic cells.

Well-differentiated tumors resemble their tissue of origin

Poorly-differentiated or undifferentiated (anaplastic) tumor cells appear primitive and lack specialization along any particular cell line.

49. Which level of prolactin definitely suggest prolactinoma?

a) 300 ng/ml

b) 150 ng/ml

c) 200 ng/ml

d) 100 ng/ml

Correct Answer - C

Answer: C - 200 ng/ml

Prolactinomas are the most common type of hyperfunctioning pituitary adenoma.

Benign tumors of pituitary gland producing prolactin.

Hyperprolactinemia causes amenorrhea, galactorrhea, loss of libido, and infertility.

Because many manifestations of hyperprolactinemia (e.g., amenorrhea) are more obvious in premenopausal women than in men or postmenopausal women, prolactinomas usually are diagnosed at an earlier stage in women of reproductive age than in other persons so affected.

Higher blood prolactin concentrations are seen.

mild elevations of serum prolactin (less than 200 $\mu\text{g/L}$) in a patient with a pituitary adenoma do not necessarily indicate a prolactin-secreting neoplasm.

50. Laxative abuse causes which of the following renal stones ?

a) Uric acid

b) Ammonium urate

c) Struvite

d) Ca oxalate

Correct Answer - B

Answer: B - Ammonium urate

Based on the chemical nature two types of kidney stones:

- Calcium oxalate (majority).
- Others include Uric acid, Struvite (Infected stones), and Cystine stones (rare hereditary metabolic disorder)

Characteristic stone formation in laxative abuse:

- Laxative abuse acts a factor in kidney stone formation.
- Laxative abuse causes potassium loss
- As a compensation mechanism kidney produces large amount of ammonium.
- Resulting in formation of uncommon stone type - ammonium acid urate.

51. Which of the following can result in dactylitis

a) Hemophilia

b) Von willebrand disease 1

c) Measles

d) Sickie Cell Anemia

Correct Answer - D

Answer: D - Sickie Cell Anemia

Dactylitis (Hand-Foot Syndrome) is seen in sickle cell anemia
Severe pain affecting the bones of hands, feet, or both.
Often 1st symptom of sickle cell anemia in babies.

52. Which chromosome is responsible for the production of MIF?

a) Chromosome 16

b) Chromosome 22

c) X Chromosome

d) Y chromosome

Correct Answer - D

Answer: D - Y Chromosome

Anti-Mullerian Hormone (AMH) / Mullerian Inhibiting Factor (MIF);
Mullerian-inhibiting Hormone (MIH) / Mullerian-inhibiting Substance (MIS).

AMH - Downstream genes regulated by SRY pathway

SRY - Gene in "Sex determining region" - short arm of Y chromosome - Testis determining factor.

Secreted by Sertoli cells of the testes.

The production of AMH is controlled by two autosomal gene loci.

Hormone code

Receptor code.

Glycoprotein hormone

Related to inhibin & activin

Member of the transforming growth factor- β (TGF- β)

Key roles are in growth differentiation and folliculogenesis.

53. Site of action of amphotericin B is:

a) Ribosomes

b) Cell wall

c) Plasma membrane

d) Protein

Correct Answer - B

Answer:- B - Cell wall

Polyene drug compounds like Amphotericin B acts on cell membrane -

- Amphotericin B, antifungal agent.
- Chemically a polyene compound
- Obtained from *Streptomyces nodosus*.
- Polyenes have a high affinity for “ergosterol” present in the fungal cell membrane.
- Binds and gets inserted into the cell membrane forming “Micropore”.
- Marked increase in permeability of cell membrane.
- Polyene drug compounds like Amphotericin B acts on cell membrane
- Amphotericin B, antifungal agent.
- Chemically a polyene compound
- Obtained from *Streptomyces nodosus*.
- Polyenes have a high affinity for “ergosterol” present in the fungal cell membrane.
- Binds and gets inserted into the cell membrane forming “Micropore”.
- Marked increase in permeability of cell membrane.

54. Which antiretroviral drug also has anti hepatitis activity?

a) Abacavir

b) Tenofovir

c) Nevirapine

d) Emtricitabine

Correct Answer - D

Answer: D - Emtricitabine

Emtricitabine, NRTI drug with both antiretroviral & anti-hepatitis properties

- Nucleoside reverse transcriptase inhibitor for the prevention and treatment of HIV infection in adults and children.
- Also used in combination with tenofovir

55. Drug of choice for resistant rheumatic chorea?

a) Valproate

b) Haloperidol

c) Diazepam

d) Probenecid

Correct Answer - A

Answer: - A - Valproate

- **Valproate**, Sulpiride, & diazepam are used for symptomatic treatment.

Acute Rheumatic Fever:

- Abnormal immune response to group A streptococcal infection
- Commonly affecting the joints, heart, brain, and skin.
- **Symptoms:** Arthritis, related to carditis & **chorea**.

Sydenham's chorea / Chorea minor

- Characterized by rapid, uncoordinated jerking movements primarily affecting the face, hands and feet.
- Signs & symptoms of chorea usually do not respond well to treatment with antirheumatic agents
- **Symptomatic treatment include anticonvulsants (eg, valproate, carbamazepine)** and neuroleptics (eg, pimozide, haloperidol, risperidone, olanzapine)

56. At $pK_a = pH$ -

- a) Conc. of drug is 50% ionic and 50 % non-ionic
- b) Absorption of drug is 50% ionic and 50% ionic
- c) Conc of drug is 75% ionic and 25 % non-ionic
- d) Conc of drug is 25% ionic and 75 % non-ionic

Correct Answer - A

Answer: A - Concentration of drug is 50% ionic & 50 % Non-ionic

Numerically equal pK_a & pH represents 50% drug ionization

- pK_a is negative logarithm of acidic dissociation of weak electrolyte.
- **On equal concentrations of ionized & unionized drugs, $\log 1$ is zero.**
- Thus, when pK_a is numerically equal to pH
- **($pK_a = pH$) \rightarrow 50 % drug is ionized.**

57. Physiological dose of hydrocortisone (mg/kg/day) is -

a) 5 mg/kg/day

b) 10 mg/kg/day

c) 15 mg/kg/day

d) 20 mg/kg/day

Correct Answer - B

Answer:- B - 10 mg/kg/day

The normal rate of secretion of two principle corticoids

Hydrocortisone - 10 mg/kg/day (nearly half in morning hours)

Aldosterone - 0.125 mg/daily

58. What is mechanism of action of colchicine in acute gout?

- a) Inhibition of purine metabolism
- b) Inhibition of uric acid conversion
- c) Migration of leukocytes
- d) Leukocytes, lymphocytes inhibition & microtubular inhibitor

Correct Answer - D

Answer: D - Leukocytes, Lymphocytes migration inhibition & microtubular inhibitor.

Colchicine acts by inhibiting the granulocyte migration into the inflamed joint.

- An alkaloid from *Colchium autumnale*
- **Specifically suppresses gouty inflammation.**
- Doesn't inhibit the synthesis or promote the excretion of uric acid.

Mechanism of action:

- **Colchicine acts by, inhibits the release of glycoprotein**
- **Binds to fibrillar protein tubules inhibiting granulocyte migration into the inflamed joint.**
- An acute attack of gout starts by precipitation of urate crystals in synovial fluid.
- Inflammatory response starts with granulocyte migration into joint
- Phagocytosing urate crystals releasing glycoprotein
- Glycoprotein increases lactic acid production and releasing lysosomal enzymes causing more joint destruction.

59. Basiliximab is an -

a) IL-1 receptor antagonist

b) Anti-CD3 antibody

c) IL-2 receptor antagonist

d) TNF inhibitor

Correct Answer - C

Answer:- C - IL-2 receptor antagonist

Basiliximab exhibits high affinity towards IL-2 receptor, inhibiting it.

- Anti- CD-25 antibody
- **High affinity for IL-2 receptor**
- Short plasma half life - 1 week
- Useful in preventing transplant rejection reactions.
- Adverse effects - Anaphylactic reactions & opportunistic infections.

60. Pirenzapine is used -

a) Gastric ulcer

b) Glaucoma

c) Hypertension

d) Congestive cardiac failure

Correct Answer - A

Answer: A - Gastric Ulcer

Pirenzepine, a selective M1 anticholinergic drug inhibiting gastric acid secretion.

- Low therapeutic dose range.
- **Used for treating gastric ulcer.**

61. Which of the following antipsychotic have increased prolactin secretion -

a) Olanzapine

b) Ziprasidone

c) Clozapine

d) Risperidone

Correct Answer - D

Answer:- D - Risperidone

Significant rise in prolactin levels during risperidone therapy is observed.

- **Risperidone** - Antipsychotic drug with combined 5-HT 2a and dopamine D2 antagonist activity
- High affinity to α_1 , α_2 and H1 receptors
- More potent D2 blocker than clozapine
- Ameliorates symptoms of schizophrenia
- **Prolactin levels rise during risperidone therapy, but less epileptogenic than clozapine.**
- Produces extrapyramidal side effects are less only at lower doses (<6 mg/day).
- Blockade of these contribute to efficacy and side effects like postural hypotension.
- Frequently causes agitation.

62. Which of the following is glucocorticoid synthesis inhibitor?

a) Mifepristone

b) Flutamide

c) Finasteride

d) Metyrapone

Correct Answer - D

Answer: D - Metyrapone

Inhibits 11 β -Hydroxylase in adrenal cortex

Prevents the synthesis of hydrocortisone

63. Which of the following statements is incorrect w.r.t Prasugrel?

- a) Not a prodrug
- b) P2Y purinergic receptor blocker
- c) Has a strong antiplatelet activity
- d) Causes intracranial hemorrhage in TIA patients.

Correct Answer - A

Answer: A - Not a prodrug

Prasugrel is a prodrug , similar to Clopidogrel

Thienopyridine drug class

Irreversible antagonist of P2Y₁₂ ADP receptors

Rapidly absorbed, completely activated & exerts more consistent platelet inhibition.

Strong anti-platelet activity

Bleeding complications are more serious and frequent.

Contraindicated in patients with history of ischemic strokes and TIA's

64. Q-T elongation is seen in which drug?

a) Quinidine

b) Amiodarone

c) Magnesium Sulfate

d) Lignocaine

Correct Answer - A

Answer: A - Quinidine

Specific pattern of Q-T prolongation is referred to as “Torsades de pointes”

Drugs causing Torsades de Pointes

- **Quinidine (most common)**
- Sotalol
- Procainamide
- Disopyramide
- Phenothiazines
- Tricyclic antidepressants

65. Sacubitril is,

- a) ACE inhibitor
- b) Neutral endopeptidase inhibitor
- c) Calcium channel inhibitor
- d) Beta adrenergic blocker

Correct Answer - B

Answer: B - Neuro-endopeptidase inhibitor

Sacubitril, a prodrug inhibiting neuro-endopeptidase enzyme

Activated to Sacubitril,

Inhibiting enzyme neprilysin (Neutral endopeptidases)

Combination drug used in heart failure patients

Usually combined with ACE inhibitors like valsartan in ratio of 1:1

66. Niacin therapy is contraindicated in diabetes because -

- a) Increases the blood sugar levels
- b) Causes scleroderma
- c) Difficult to give injection
- d) Increases the metabolism of oral hypoglycemic drugs

Correct Answer - A

Answer: A - increases the blood sugar levels

Niacin therapy has potential effects on blood sugar levels.

Increases the blood glucose levels in diabetes patients

67. Endothelin acts through which receptors?

a) cAMP

b) cGMP

c) Na⁺ receptors

d) Calcium receptors

Correct Answer - A

Answer: A - cGMP

Endothelin-1 (ET-1) is a potent endogenous vasoconstrictor, mainly secreted by endothelial cells.

68. Which is the centrally acting alpha 2 agonist muscle relaxant -

a) Diazepam

b) Bromocriptine

c) Tizanidine

d) Methocarbamol

Correct Answer - C

Answer: -C- Tizanidine

Central alpha 2 adrenergic agonist

Mechanism of action:

- Inhibits the release of excitatory amino acids in spinal interneurons
- Facilitates the inhibitory transmitter glycine
- Inhibits postsynaptic reflexes
- Reducing muscle tone, frequency of muscle spasms without reducing the strength of muscle.

Indications:

- Spasticity in neurological disorders
- Painful muscle spasm of spinal origin.

Contraindications:

- Patients on antihypertensives specially clonidine.

69. Apixaban is -

a) Antithrombin inhibitor

b) Direct Xa inhibitor

c) Platelet activator

d) Clotting Factor XII

Correct Answer - B

Answer: B - Direct Xa inhibitor

Direct Xa inhibitor

- Anticoagulant for treatment & prophylaxis of venous thromboembolic events
- DVT & PE

70. Anaerobes are resistant intrinsically against -

a) Beta lactam antibiotics

b) Aminoglycosides

c) Azithromycin

d) Metronidazole

Correct Answer - B

Answer: B - Aminoglycosides

Anaerobic bacteria particularly are resistant to aminoglycosides due to lack of oxidative mechanism to drive drug uptaking process.

Intrinsic resistance / Insensitivity:

- Innate ability of bacteria to resist activity of particular antimicrobial agent
- Inherent structural or functional characteristics allows for tolerance of a particular drug or antimicrobial class. i.e., Susceptibility to that particular drug is reduced.

71. Which is not bacteriostatic antibiotic -

a) Clindamycin

b) Vancomycin

c) Tetracycline

d) Cephalosporins

Correct Answer - B

Answer: B- Vancomycin

Bacteriostatic antibiotics

- **Limit bacterial growth by interfering with bacterial protein production, DNA replication,** or other aspects of bacterial cellular metabolism.
- Tetracyclines, sulfonamides, clindamycin, spectinomycin, trimethoprim, chloramphenicol, macrolides and lincosamides.

Bactericidal antibiotics

- **Inhibit cell wall synthesis** (Irreversible killing)
- Aminoglycosides. cephalosporins. fluoroquinolones. metronidazole. penicillin. vancomycin

72. Which of the following causes melanosis coli?

a) Senna

b) Sorbitol

c) Magnesium Sulphate

d) Bisacodyl

Correct Answer - A

Answer: A - Senna

Laxative abuse with drugs like senna cause melanosis coli

- **Anthranoid laxatives (aloe, cascara sagrada, and senna) are derived from naturally occurring plants**
- **Considered to be stimulant laxatives.**
- **Safer short term use.**
- **Long term abuse can cause melanosis coli & possibly increases risk of colonic cancer.**

73. Which among the following will the choice of antibiotic for a bedridden patient with catheter-related UTI and pneumonia.

a) Amoxicillin

b) Beta Lactam antibiotics with beta lactamase

c) 3rd gen cephalosporins

d) 2nd gen cephalosporins

Correct Answer - B

Answer: B - Beta Lactam Antibiotics

Contains beta lactamase enzyme for potent action against organisms causing UTI

74. Mycoplasma is resistant to -

a) Ceftriaxone

b) Cephalosporins

c) Aminoglycosides

d) Fluoroquinolones

Correct Answer - A

Answer: A - Ceftriaxone

Mycoplasma shows resistance towards **Ceftriaxone, a third generation cephalosporin (beta lactam antibiotic)**

Lack of cell wall in mycoplasmas makes them intrinsically resistant to β -lactams & to all antimicrobials that target cell wall.

Mycoplasma pneumoniae:

- Mycoplasma pneumoniae is a pathogenic mycoplasma responsible for respiratory tract infections in humans.
- **First -line treatment:** macrolides & related antibiotics, tetracyclines and fluoroquinolones is preferred.

75. Tadalafil should not be given with:

a) Vasodilator

b) Antibiotics

c) Vasoconstrictors

d) Valproate

Correct Answer - A

Answer: A - Vasodilators

Combination with vasodilators results in sudden changes of blood pressure values

Tadalafil relaxes muscles of the blood vessels and increases blood flow to particular areas of the body.

Used to treat erectile dysfunction (Impotence), and symptoms of benign prostatic hypertrophy (Enlarged prostate)

Eg: Taking tadalafil with vasodilator drug like nitrate can cause sudden & serious decrease in blood pressure.

76. Estimate volume of ringer lactate in first 8 hrs for 40% burns in 50 kg male with 2° burns?

a) 8 lt

b) 4 lt

c) 2 lt

d) 6 lt

Correct Answer - B

Answer: B. 4 lt

Parkland formula most commonly used IV fluid - Lactated Ringer's Solution

Fluid calculation

- $4 \times \text{weight in kg} \times \% \text{TBSA burn}$
- Give $1/2$ of that volume in the first 8 hours
- Give other $1/2$ in next 16 hours
- Warning: Despite the formula suggesting cutting the fluid rate in half at 8 hours, the fluid rate should be gradually reduced throughout the resuscitation to maintain the targeted urine output, i.e., do not follow the second part of the formula that says to reduce the rate at 8 hours, adjust the rate based on the urine output.

Example of fluid calculation

- 50-kg man with 40% TBSA burn

Parkland formula:

- $4 \times 50 \times 40 = 8,000 \text{ ml}$
- Give $1/2$ in first 8 hours = 4,000 ml in first 8 hours
- Adjust fluid rate to maintain urine output of 50 ml/hr

77. Posthumous child is:

- a) Child delivered after death of biological mother
- b) Child delivered after death of biological father
- c) Born after death of parents
- d) has been abandoned by parents

Correct Answer - B

Answer: B. Child delivered after death of biological father

A child born after death of his/ her biological father

78.

M'naghten rule comes under which section of IPC?

a) Crpc 84

b) C pc 48

c) Ipc 84

d) IPC 48

Correct Answer - C

Answer: C. Ipc 84

M'naghten rule (legal test or right or wrong test) :

- It states that an accused person is not legally responsible, if it is clearly proved that at the time of committing the crime, person was suffering from such a defect of reason from abnormality of mind that he didn't know the nature and quality of act he was doing or that what he was doing was wrong i.e. a person is not responsible if he is not of sound mind.
- It is accepted in india as law of criminal responsibility and is embodied in section 84 1PC as - "nothing is an offence which is done by a person, who at the time of doing it, by reason of unsoundness of mind is incapable of knowing the nature of act, or that he is doing what is either wrong or contrary to law".

79. Bluish discoloration of gastric mucosa seen in which poisoning?

a) Mercury

b) Cadmium

c) Amytal sodium

d) Arsenic

Correct Answer - C

Answer: C. Amytal sodium

S. No.	Poison	Color
1.	Copper sulfate, amytal capsule	Blue
2.	Ferrous sulfate	Green
3.	Sulphuric hydrochloric/acetic acid	Black/charred
4.	Nitric acid	Yellow
5.	Carbolic acid	Buff/white
6.	Arsenic	White particles
7.	Mercury	Slate
8.	Cresols	Brown

80. Muscle pain, nephropathy caused by which metal poisoning

a) Arsenic

b) Cadmium

c) Mercury

d) Lead

Correct Answer - A

Answer: A. Arsenic

Nephropathy is caused by most of heavy metals. Muscle pain is associated with arsenic.

81. Which is the first organ to putrefy :

a) Brian

b) Heart

c) Prostate

d) Kidney

Correct Answer - A

Answer: A. Brian

The order of putrefaction is - earliest to last → larynx, trachea → Stomach, intestine → liver, spleen → Brain, Lungs → Heart, Kidney → Bladder, Uterus/Prostrate → Skin, muscles, tendon → lastly, bones.)

82. Locard is famous for:

- a) Theory of exchange
- b) Fingerprint study
- c) Formula for estimation of stature
- d) System of personal identification using the body measurement

Correct Answer - A

Answer: A. Theory of exchange

Edmund locard is famous for theory of exchange.

83. When does basiocciput fuses with basisphenoid?

a) 18 to 22

b) 22 to 25

c) 14-16

d) 12-14

Correct Answer - A

Answer: A. 18 to 22

The basioccipital fuses with the basisphenoid at about 18 to 21 years.

84. What is the smell of mummified body?

a) Odourless

b) Putrid

c) Pungent

d) Offensive

Correct Answer - A

Answer: A. Odourless

A **mummy** will smell odourless, this is because the internal organs are removed (which are the biggest factors in the decay process) and replaced with natron (which dries them out, preventing 'proper' decay). The rest of the **body** is also dried using natron.

85. Patient presented with proximal tubule proteinuria. Which metal is likely to be associated with it?

a) Cadmium

b) Mercury

c) Gold

d) Lead

Correct Answer - A

Answer: A. Cadmium

Early kidney damage and proteinuria seen in people, occupationally or environmentally exposed to **cadmium**.

86. Which of the following constitutional article is not related to children:

a) 23

b) 21-A

c) 42

d) 24

Correct Answer - C

Answer: C. 42

Constitutional Guarantees that are meant specifically for children include:

- Right to free and compulsory elementary education for all children in the 6-14 year age group (Article 21 A)
- Right to be protected from any hazardous employment till the age of 14 years (Article 24)
- Right to be protected from being abused and forced by economic necessity to enter occupations unsuited to their age or strength (Article 39(e))
- Right to equal opportunities and facilities to develop in a healthy manner and in conditions of freedom and dignity and guaranteed protection of childhood and youth against exploitation and against moral and material abandonment (Article 39 (f))
- Right to early childhood care and education to all children until they complete the age of six years (Article 45)

Besides, Children also have rights as equal citizens of India, just as any other adult male or female:

- Right to equality (Article 14)
- Right against discrimination (Article 15)
- Right to personal liberty and due process of law (Article 21)

- Right to being protected from being trafficked and forced into bonded labour (Article 23)
- Right of minorities for protection of their interests (Article 29)
- Right of weaker sections of the people to be protected from social injustice and all forms of exploitation (Article 46)
- Right to nutrition and standard of living and improved public health (Article 47)

87. Which of the statement regarding Factory act is correct

- a) Child age less than 14 carrying serious work earn more money
- b) Less than 14 yr not done for factory act
- c) More than 72 hour work per week
- d) More than 82 hours a week

Correct Answer - B

Answer: B- Less than 14 yr not done for factory act

The Factory Act prohibits the employment of children below 14 years and declares 15 to 18 years as belonging to the adolescent group. Adolescents require fitness certificate prior to employment in a job. Act also prescribed a maximum 48 hours per week, not exceeding 9 Hours per day with at least half hour rest after 5 hour continuous work.

88. Burkholderia cepacia is resistant to which of the following drugs:

a) Ceftazidime

b) Trimethoprim-sulfamethoxazole

c) Temocillin

d) Cefotetan

Correct Answer - D

Answer: D. Cefotetan

B. cepacia complex strains are intrinsically resistant to a wide range of antimicrobial agents, including aminoglycosides, polymyxin, first and second generation cephalosporins, and carboxypenicillins

Antimicrobial agents that are effective against B. cepacia complex include meropenem, ceftazidime, piperacillin, temocillin, and trimethoprim-sulfamethoxazole.

89. Shingles Is caused by which of the following ?

a) Varicella-zoster

b) Herpes simplex

c) CMV

d) None

Correct Answer - A

Ans. A. Varicella-zoster

Shingles, also called herpes zoster, is a painful skin rash.

Shingles is caused by reactivation of the varicella zoster virus, the same virus that causes chickenpox.

90. Urea breath test is used for diagnosis of:

a) H.pylori

b) Campylobacter jejuni

c) E. coli

d) Lactobacillus

Correct Answer - A

Answer: A. H.pylori

The urea breath test is a rapid diagnostic procedure used to identify infections by *Helicobacter pylori*, a spiral bacterium implicated in gastritis, gastric ulcer, and peptic ulcer disease. It is based upon the ability of *H. pylori* to convert urea to ammonia and carbon dioxide

91. Hyperacute graft rejection occurs after how much time?

a) 24 hours

b) 2 weeks right

c) In minutes

d) Years

Correct Answer - C

Answer: C. In minutes

Hyperacute Transplant Rejection occurs almost immediately and is often evident while you are still in surgery. It is caused by accidental ABO Blood type mismatching of the donor and recipient which almost never happens anymore..Acute onset is in few weeks to month. Chronic onset is from months to years.

92. Australian antigen for hepatitis b is?

a) Hb S ag

b) Hb E ag

c) Hb D ag

d) HbV Dna

Correct Answer - A

Answer: A. Hb S ag

HBsAg (also known as the Australia antigen) is the surface antigen of the hepatitis B virus (HBV). It indicates current hepatitis B infection.

93. Which fungus is most commonly associated with orbital cellulitis in patients with diabetic ketoacidosis.

a) Candida

b) Mucor

c) Aspergillus

d) Rhizopus

Correct Answer - C

Answer: C. Aspergillus

Orbital cellulitis term is reserved for infections behind the orbital septum which may or may not spill over to lids. Bacterial OC is more common in children and fulminant infection (& ischemic infarction) with Mucor or Aspergillus typically affect patients with diabetes (esp ketoacidosis) and *immunosuppression*. Presentation is Extensive swelling of lids with chemosis often obscure proptosis (i.e. most commonly lateral & downwards). Proptosis with impaired mobility resulting in diplopia Pain is severe, increased by movement of eye or pressure Unilateral, tender, warm & red periorbital edema, painful ophthalmoplegia.

94. Sabin Feldman dye test is used for diagnosis of which of the following condition:

a) Botulism

b) Toxoplasmosis

c) Sarcoidosis

d) Yellow fever

Correct Answer - B

Answer: B. Toxoplasmosis

A **Sabin–Feldman dye** test is a serologic test to diagnose for toxoplasmosis

95. Acute Hemorrhagic Conjunctivitis is caused by which of enterovirus type ?

a) 69

b) 68

c) 70

d) 71

Correct Answer - C

Answer: C. 70

Acute hemorrhagic **conjunctivitis** (AHC) is characterized by **conjunctival** congestion, vascular dilatation, and onset of edema. Serologic studies have been useful in showing the presence of neutralizing antibodies to Coxsackie group A24 (CA24) and enterovirus **E70 (EV70)** strains as the causative agent.

96. Echinococcus granulosus are commonly seen in which of the given animals:

a) Dog

b) Cat

c) Fox

d) Pig

Correct Answer - A

Answer: A. Dog

Echinococcus granulosus, also called the hydatid worm, hyper tape-worm or **dog** tapeworm. Domestic **dogs** (*Canis familiaris*) have been recognised as the definitive host of the parasite.

97. An anaerobe causing multiple abscess with discharging sinuses, demonstrating sulphur granules in pus is?

a) Actinomyces

b) Nocardia

c) Salmonella

d) Tularemia

Correct Answer - A

Answer: A. Actinomyces

Actinomycosis is a rare subacute to chronic infection caused by the gram-positive filamentous non-acid fast anaerobic to microaerophilic bacteria, *Actinomyces*.

The chronic form has multiple abscesses that form sinus tracts and are associated with sulfur granules. About 70% of infections are due to either Actinomyces israelii or Actinomyces gerencseriae.

The characteristic of the disease is the sulfur granules which are yellow. They are formed primarily by mycelial fragments with some proteinaceous polysaccharide complexes, which act as a resistance mechanism to avoid and inhibit phagocytosis.

Multiple abscess with discharging sinuses, demonstrating sulphur granules in pus are characteristics of actinomyces

98. Whole blood is used as a sample for which test?

a) Bacteria

b) IGRA

c) Genexpert

d) Virus

Correct Answer - B

Answer: B. IGRA

Interferon-Gamma Release Assays (IGRAs) are whole-blood tests that can aid in diagnosing *Mycobacterium tuberculosis* infection

99. Which organism causing acute bacterial prostatitis ?

a) Enterococcus

b) Streptococcus viridans

c) Peptostreptococcus

d) E.coli

Correct Answer - D

Answer: D. E.coli

Aerobic gram-negative bacilli are the predominant pathogens in bacterial prostatitis. E. coli **cause** 50%–80% of cases; other pathogens include Enterobacteriaceae (eg, Klebsiella and Proteus, which account for 10%–30% of cases), Enterococcus species (5%–10%)

100. Which of the following organism releases histamine and cause scombroid fish poisoning -

a) Salmonella

b) Staphylococcus

c) P. aeruginosa

d) Weissella

Correct Answer - C

Answer: C. P. aeruginosa

Scombroid poisoning is one of the most common **causes** of morbidity associated with **fish** intake which have not been refrigerated properly from the time they were caught until the time they were served. Bacteria act on compounds in the fish, releasing histamine. Process is induced by enzymes produced by primarily enteric gram-negative **bacteria** (e.g., Morganella morganii, Escherichia coli, Klebsiella species and Pseudomonas aeruginosa) found in the **fish's** cutis and intestines.'.

101. Who is the father of microbiology?

- a) A.V.L.hook
- b) Robert brown
- c) J.C Bose
- d) Pasteur

Correct Answer - A

Answer: A. A.V.L.hook

“Antoni van Leeuwenhoek” is commonly known as “the Father of Microbiology.

Antonie Philips van Leeuwenhoek (24th Oct, 1632 – 26th Aug, 1723) is known as 'The Father of Microbiology'. He was known so because of his contributions towards the establishment of microbiology. He was scientist from Delft, Netherlands and is considered to be 'The First Microbiologist in the World'.

leeuwenhoek is called as father of microbiology. He was the first person to see bacteria through his self made single lensed microscope. And he named them “animalcules”. **Louis Pasteur** is know as “father of morden microbiology”.

102. Cutaneous larva migrans caused by which organism?

- a) Strongyloides
- b) Toxocara canis
- c) Ancylostoma braziliense
- d) Necator americanus

Correct Answer - C

Answer: C. Ancylostoma braziliense

Cutaneous larva migrans (CLM)

- It is a skin disease in humans, caused by the larvae of various nematode parasites of the hookworm family (Ancylostomatidae).
- The most common species causing this disease in the Americas is Ancylostoma braziliense.
- These parasites live in the intestines of dogs, cats and wild animals and should not be confused with other members of the hookworm family for which humans are definitive hosts, namely Ancylostoma duodenale and Necator americanus.
- Colloquially called creeping eruption due to its presentation, the disease is also somewhat ambiguously known as "ground itch" or (in some parts of the Southern USA) "sandworms", as the larvae like to live in sandy soil.
- Another vernacular name is plumber's itch.
- The medical term CLM literally means "wandering larvae in the skin"

103. After kidney transplantation which organisms infection is more likely to happens -

a) CMV

b) Klebsiella

c) Streptococcus

d) Staphylococcus

Correct Answer - A

Answer: A. CMV

CMV is the most common viral infection after Kidney Transplantation. Most common CMV syndrome in kidney transplant patient is fever (most common), leukopenia, hepatosplenomegaly, myalgia and arthralgia.

104. Incidence of a disease is 4 per 1000 of population with duration of 2 years. Calculate the prevalence?

a) 8/1000

b) 4/1000

c) 2/1000

d) 6/1000

Correct Answer - A

Ans. A. 8/1000

Prevalence = (Incidence Rate) x (Average Duration of Disease)

105. Cytotoxic and expired drug disposal is done by which method?

a) Dumping

b) Autoclave

c) Landfill

d) Burning

Correct Answer - C

Ans.C. Landfill

Colour coding	Type of Container	Waste Category	Treatment options
Yellow	Plastic Bags	Human and animal wastes, Microbial and Biological wastes and soiled wastes (Cat 1,2,3 and 6)	Incineration/ Deep Burial
Red	Disinfected container/ Plastic bags	Microbiological and Biological wastes, Soiled wastes, Solid wastes (Cat 3,6,7)	Autoclave/ Microwave/ Chemical Treatment)
Blue/ White/ Transparent	Plastic bag, Puncture proof container	Waste sharps and solid waste (Cat 4 &7)	Autoclave/ Microwave/ Chemical Treatment Destruction and Shredding
		Discarded	

Black	Plastic bag	medicines, Cytotoxic drugs, Incineration ash and chemical waste (Cat 5,9 & 10)	Disposal in secured land fills
Green	Plastic Container	General waste such as office waste, food waste & garden waste	Disposed in secured landfills

106. For NRR to be 1 couple protection rate should be?

a) 50%

b) 60%

c) 55%

d) 75%

Correct Answer - B

Ans. B. 60%

Couple Protection Rate (CPR)

- It is an indicator of the prevalence of contraceptive practice in the community
- Definition: the percentage of eligible couples effectively protected against childbirth by one or the other approved methods of family planning
- Sterilization
- IUD
- Condom
- OCP's
- $NRR = 1$ can be achieved only if the $CPR > 60\%$

107. New RNTCP software online to monitor TB control programme is-

a) NIKSHAY

b) NICHAY

c) E- DOTS

d) NIRBHAI

Correct Answer - A

Ans. A.NIKSHAY

To keep a track of the TB patients across the country, the Government of India has introduced a system called NIKSHAY. The word is combination of two Hindi words NI and KSHAY meaning eradication of tuberculosis.

NIKSHAY (www.nikshay.gov.in) is a web enabled application, which facilitates monitoring of universal access to TB patients data by all concerned.

The system has been developed jointly by the Central TB Division of the Ministry of Health and Family Welfare and National Informatics Centre (NIC) and it was launched by the Government of India in June 2012 with issue of required administrative directions from Central TB Division for use of NIKSHAY

108. Study unit of ecological study is

a) Population

b) Patient

c) Community

d) Case

Correct Answer - A

Ans. A.Population

In ecological studies the unit of observation is the population or community.

Disease rates and exposures are measured in each of a series of populations and their relation is examined.

Often the information about disease and exposure is abstracted from published statistics.

109. In a screening test for DM out of 1000 population, 90 were positive. Then the gold standard test was done in which 100 were positive. Calculate the sensitivity?

a) 90/100

b) 100/110

c) 80/100

d) 100/100

Correct Answer - A

Ans. A. 90/100

		The Truth		
		Has the disease	Does not have the disease	
Test Score:	Positive	True Positives (TP) a	False Positives (FP) b	$PPV = \frac{TP}{TP + FP}$
	Negative	False Negatives (FN) c	True Negatives (TN) d	
		Sensitivity $\frac{TP}{TP + FN}$ Or, $\frac{a}{a + c}$	Specificity $\frac{TN}{TN + FP}$ $\frac{d}{d + b}$	$NPV = \frac{TN}{TN + FN}$

So, True positive (a)= 90
False negative(c)=10

$$\text{Sensitivity} = a/(a+c)=90/100$$

110. What is the mass chemoprophylaxis for meningococcal meningitis ?

a) Rifampicin

b) Chloramphenicol

c) Tetracycline

d) Penicillin

Correct Answer - A

Ans. A.Rifampicin

Recommended Chemoprophylaxis for High-Risk Close Contacts:

Age	Dose	Duration	Cautions
RIFAMPICIN:			
<1 month	5 mg/kg	Oral every 12 hrs 2 days	
>1 month	10 mg/kg	Oral every 12 hrs 2 day	Not recommended for use in pregnancy
CEFTRIAXONE:			
<15 years	125mg	IM single dose	
>15 years	250 mg	IM single dose	
CIPROFLOXACIN			
>18 years	500 mg	Oral single dose	Not recommended for use in pregnancy

111. Which among the following is an active form of chlorination?

a) Hypochlorite ion

b) Hydrogen chloride

c) Hypochlorous acid

d) Chloride ion

Correct Answer - C

Ans. C. Hypochlorous acid

The disinfecting action of chlorine is predominantly due to hypochlorous acid.

Hypochlorous acid is the most effective form of chlorine and it is almost 70-80 times more effective than hypochlorite ions.

112. Kala-Azar is found in all endemic areas except.

a) West Bengal

b) UP

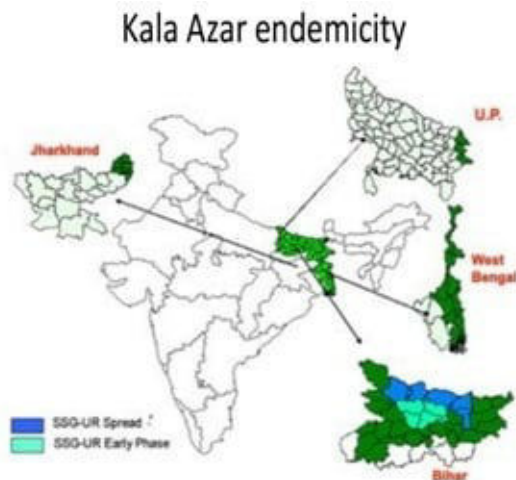
c) Bihar

d) Assam

Correct Answer - D

Ans. D. Assam

UP , West Bengal Bihar And Jharkhand are the endemic states of kala Azar



113. Risk among exposed to risk among non exposed is defined to be –

a) Relative risk

b) Odds ratio

c) Attributable risk

d) None of the above

Correct Answer - A

Ans.A. Relative risk

$$RR = \frac{P \text{ event when exposed}}{P \text{ event when not exposed}}$$

In statistic and epidemiology , **relative risk** or **risk ratio (RR)** is the ratio of the probability of an event occurring (for example, developing a disease, being injured) in an exposed group to the probability of the event occurring in a comparison, non-exposed group.

- RR = 1 means that exposure does not affect the outcome
- RR < 1 means that the risk of the outcome is decreased by the exposure
- RR > 1 means that the risk of the outcome is increased by the exposure

114. Pasteurization is done at-

a) 73 °C For 20 min

b) 63 °C For 30 min

c) 72 °C For 30 seconds

d) 63°C For 30 seconds

Correct Answer - B

Ans.B. 63 °C For 30 min

Pasteurization of milk, widely practiced in several countries, notably the United States, requires temperatures of about 63° C (145° F) maintained for 30 minutes or, alternatively, heating to a higher temperature, 72° C (162° F), and holding for 15 seconds (and yet higher temperatures for shorter periods of time).

115. Ideal time gap between 2 live vaccination

-

a) 2 weeks

b) 4 weeks

c) 8 weeks

d) 12 weeks

Correct Answer - B

Ans.B.4 weeks

If live parenteral (injected) vaccines (MMR, MMRV, varicella, zoster, and yellow fever) and live intranasal influenza vaccine (LAIV) are not administered at the same visit, they should be separated by at least 4 weeks.

116. Susceptible person developed disease within range of IP after coming in contact with primary case -

a) Secondary attack rate

b) Case fatality rate

c) Primary attack rate

d) Tertiary attack rate

Correct Answer - A

Ans. A. Secondary attack rate

Secondary Attack Rate (SAR) Number of exposed persons developing the disease within the range of the incubation period, following exposure to primary case.

117. Out of 100 women who were offered ocp for contraception 10 women got pregnant when followed for 24 months. What is Pearl's index?

a) 10

b) 5

c) 4

d) 2

Correct Answer - B

Ans. B. 5

$$\text{Pearl-Index} = \frac{\text{Number of Pregnancies} \times 12}{\text{Number of Women} \times \text{Number of Months}} \times 100$$

$$\text{Pearl Index} = 10 \times 12 \times 100 / 100 \times 24 = 5$$

118. Which of the following do not cause hardness of water ?

a) Calcium carbonate

b) Calcium sulphate

c) Calcium bicarbonate

d) Magnesium bicarbonate

Correct Answer - A

Ans. A. Calcium carbonate

Temporary hardness is a type of water hardness caused by the presence of dissolved bicarbonate minerals (calcium bicarbonate and magnesium bicarbonate).

Permanent hardness is caused by dissolved calcium sulfate (which is not removed by boiling).

119. Which of the following is not an example of direct transmission in communicable diseases ?

a) Transplacental (vertical)

b) Soil

c) Respiratory

d) STD

Correct Answer - C

Ans. C. Respiratory

The modes of transmission of infectious diseases can be classified as:

- Direct Transmission. Direct contact; Droplet infection; Contact with soil; Inoculation into skin or mucosa; Transplacental (vertical) transmission.
- Indirect Transmission. Vehicle-borne; Water; food/milk; Vector-borne. Mechanical; Biological. Airborne.

120. Water's view is used to obtain diagnostic information of:

- a) Maxillary sinus
- b) Ethmoidal sinuses
- c) Frontal sinus
- d) Sphenoid sinus

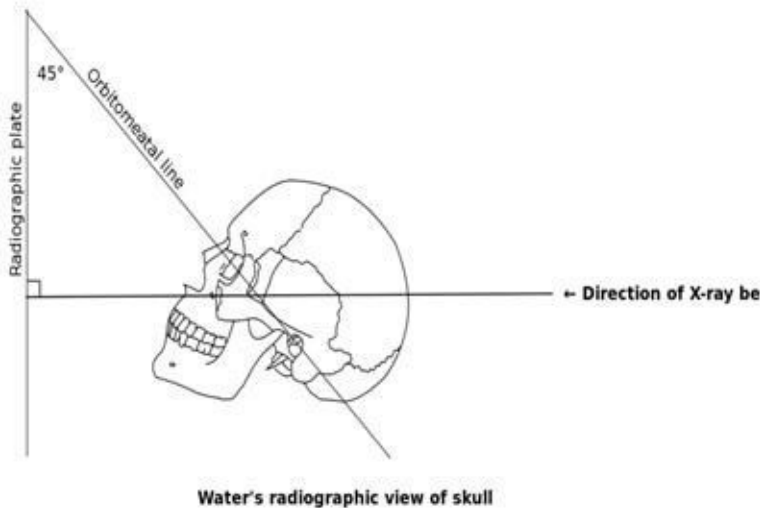
Correct Answer - A

ANSWER: A. Maxillary sinus

Waters' view (also known as the **Occipitomeatal view**) is a radiographic view, where an X-ray beam is angled at 45° to the orbitomeatal line.

The rays pass from behind the head and are perpendicular to the radiographic plate.

It is commonly used to get a better view of the [maxillary sinuses](#).



121. Tracheostomy indication is:

- a) Vocal cord replacement
- b) Pharynx replacement
- c) Tracheomalacia
- d) Foreign body obstructing airway

Correct Answer - D

Answer- D. Foreign body obstructing airway

Indications of tracheostomy:

- Upper respiratory tract obstruction; Laryngeal, supralaryngeal ,and tracheal causes.(Causes of stridor)
- Lower respiratory tract obstruction: (Secretory obstruction, Wet lung syndrome).

122. Caldwell's view is used for:

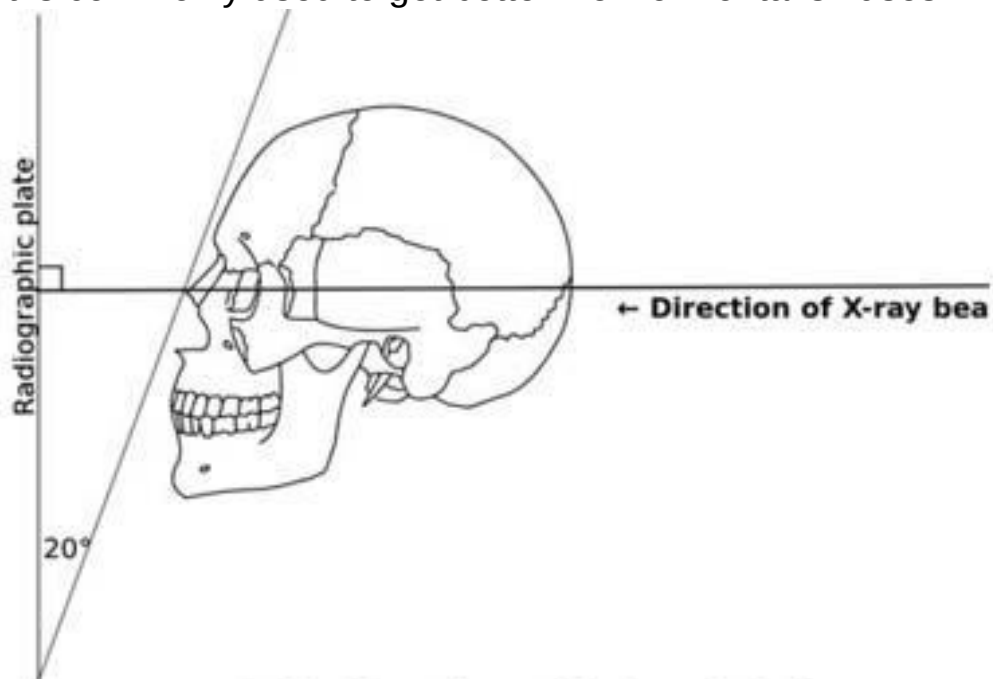
- a) Maxillary sinus
- b) Frontal sinus
- c) Ethmoidal sinus
- d) All of the above

Correct Answer - B

Answer- B. Frontal sinus

Caldwell's view (or **Occipitofrontal view**) is a radiographic view of skull, where X-ray plate is angled at 20° to orbitomeatal line. The rays pass from behind the head and are perpendicular to radiographic plate.

It is commonly used to get better view of frontal sinuses.



Caldwell's radiographic view of skull

123. Astigmatism in emmetropic eye of elderly person contribute to:

a) +1d

b) +2D

c) +3d

d) +4d

Correct Answer - C

Answer C. +3d

Laser vision enhancements

- When planning presbyopia-correcting IOL(Intra ocular lens) surgery in a patient with a high level of pre-existing astigmatism (**ie, more than 3 D**), a bioptics approach (ie, IOL followed by laser vision enhancement) may be needed.
- LRIs alone are unlikely to correct the astigmatism completely. Limbal Relaxing Incisions (**LRI**) are a refractive surgical procedure to correct minor astigmatism in the **eye**.
- There are several different strategies for these planned laser vision enhancements. The first is to perform the presbyopia-correcting IOL surgery followed by LASIK or PRK.

124. 100 day Glaucoma seen in which of the following condition:

a) Central retinal vein occlusion (CRVO)

b) Neovascular glaucoma

c) Central retinal artery occlusion (CRAO)

d) Steroid induced Glaucoma

Correct Answer - A

Answer- A, Central retinal vein occlusion (CRVO)

100 days glaucoma is a neovascular glaucoma occurring in CRVO.

Central Retinal vein occlusion (CRVO)

1. Predisposing factors:-

- Increasing age – seen in 6th - 7th-decades of life.
- Systemic hypertension is the most common cause.
- Blood dyscrasias – hyperviscosity due to chronic leukemias and polycythemia
- Raised IOP (POAG)
- Periphlebitis – sarcoidosis, Behçet's disease

2. Classification of CRVO:-

- Non – Ischemic
- Ischemic

3. Clinical Features:-

- Tortuosity and dilation of retinal veins
- Flame shaped hemorrhage – develop in the nerve fiber layer of the retina, especially around the optic disc, as a result of the high intravascular pressure that dilates the veins and collateral vessels.
- Cotton – wool spots and appearance of collaterals at the optic disc are its prominent diagnostic signs.

- Optic disc edema and hyperemia are seen.
- 4. Complications:- Rubeosis iridis and neovascular glaucoma (NVG) occur in more than 50 percent cases within 3 months (so also called as 90 days glaucoma), a few cases develop vitreous hemorrhage and proliferative retinopathy.**
- 5. Treatment:- Panretinal photocoagulation (PRP) or cryo-application, if the media is hazy, may be required to prevent neovascular glaucoma in patients with widespread capillary occlusion.**
- Photocoagulation should be carried out when most of the intraretinal blood is absorbed, which usually takes about 3-4 months.
- 100-day glaucoma or NVG results from conditions which lead to neovascularization in the eye eg. PDR, CRVO, Retinal malignancies and rarely in CRAO.
- Hemorrhagic glaucoma is also known as 100 day glaucoma** because it starts 3 months after the episode of central retinal vein occlusion.

125. Q Roth spots is seen in:

- a) Uveal melanoma
- b) Acute leukaemia
- c) Both a & b
- d) None of the above

Correct Answer - B

Answer- B. Acute leukaemia

Roth's spots are retinal hemorrhages with white or pale centers. Composed of coagulated fibrin including platelets, focal ischemia, inflammatory infiltrate, infectious organisms, or neoplastic cells. Roth's spots may be observed in leukemia, diabetes, subacute bacterial endocarditis, pernicious anemia, ischemic events, hypertensive retinopathy and rarely in HIV retinopathy. Roth's spots are named after Moritz Roth.

126. Yoke muscle of right lateral rectus:

- a) Lt medial rectus
- b) Lt superior rectus
- c) Lt lateral rectus
- d) Lt inferior oblique

Correct Answer - A

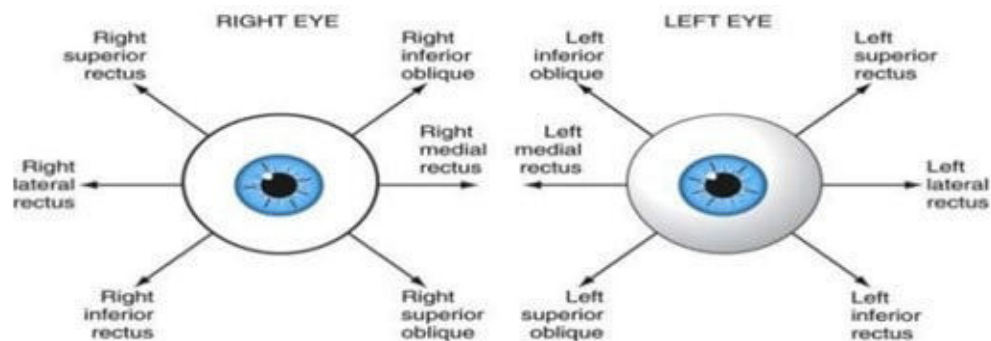
Answer - A. Lt medial rectus

Contralaterally **paired extraocular muscles** that work synergistically to direct the gaze in a given direction.

For example, in directing the gaze to the right, the right lateral rectus and left medial rectus operate together as yoke muscles.

Yoke Muscles: 2 Muscles (1 in each eye) that are the prime movers of their respective eyes in a given position of gaze

For - Example - when the eyes move into right gaze (dextroversion), the right lateral rectus & the left medial rectus muscle are yoke muscles.



127. Severe Conjunctivitis caused by:

a) Neisseria

b) Staphylococcus

c) Streptococcus

d) Haemophilus

Correct Answer - A

ANSWER- A. Neisseria

The most common causes of acute bacterial conjunctivitis are *Staphylococcus aureus*, *Streptococcus pneumoniae*, and *Haemophilus influenzae*.

Hyperacute cases are usually caused by *Neisseria gonorrhoeae* or *N. meningitidis*.

Chronic cases of bacterial conjunctivitis are those lasting longer than 3 weeks, and are typically caused by *Staphylococcus aureus*, *Moraxella lacunata*, or gram-negative enteric flora.

Neisseria gonorrhoeae causes gonococcal conjunctivitis, which usually results from sexual contact with a person who has a genital infection.

The incidence rates of gonococcal conjunctivitis increase during spring and summer.

This is a potentially devastating ocular infection, because *N. gonorrhoeae* can cause **severe ulcerative keratitis**, which may rapidly progress to corneal perforation.

128. Which is example of the Simple Myopic Astigmatism among the prescriptions given below:

a) Rx (+) sphere

b) Rx will be plano (-)

c) Rx will be (-) sphere

d) (-)(+) (+)(-) on both 90 and 180 degree axis

Correct Answer - B

Answer- B. Rx will be plano (-)

When eyewear prescriptions are written, they can be classified into different areas depending on the power or refractive error.

There are seven categories to which prescriptions can fall:

1. **Simple Hyperopia**, the Rx will be (+) sphere
2. **Simple Myopia**, the Rx will be (-) sphere
3. **Simple Myopic Astigmatism**, the Rx will be plano (-)
4. **Simple Hyperopic Astigmatism**, the Rx will be (+)
5. **Compound Hyperopic Astigmatism**, major meridian power will be (+) (+) on both 90 and 180 degree axis
6. **Compound Myopic Astigmatism**, major meridian power will be (-) (-) on both 90 and 180 degree axis
7. **Mixed Astigmatism**, major meridian powers will be opposites (-) (+) (+)(-) on both 90 and 180 degree axis

129. Blow out fracture of orbit involves:

a) Floor

b) Medial wall

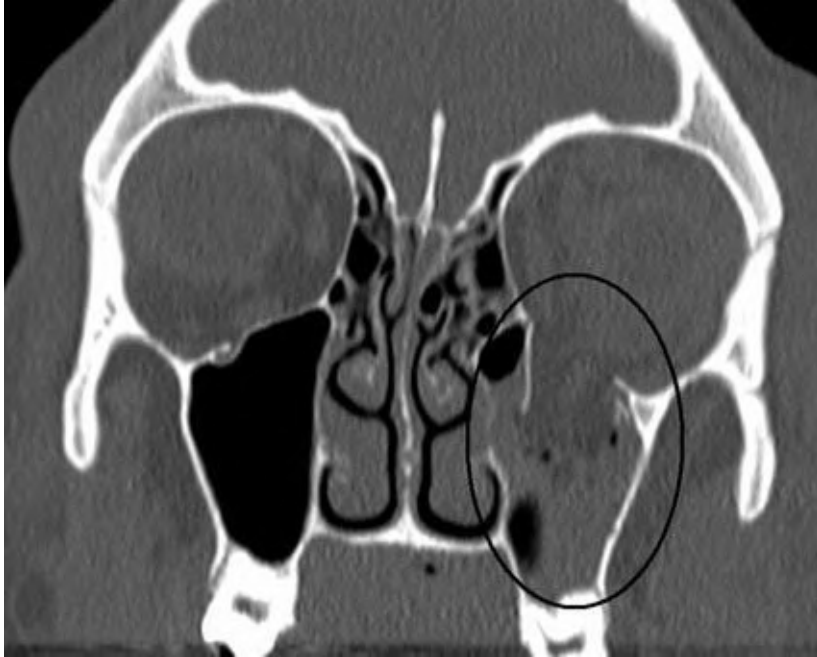c) Lateral wall

d) Roof

Correct Answer - A

Answer-A. Floor

- **Orbital floor fracture**, also known as “blowout” fracture of the orbit.
Blow out fracture of orbit involves:
 - 1. Fractures of the orbital floor are common: it is estimated that about 10% of all facial fractures are isolated orbital wall fractures (the majority of these being the orbital floor), and that 30-40% of all facial fractures involve the orbit.
 - 2. The anatomy of the orbital floor predisposes it to fracture.
 - 3. The inferior orbital neurovascular bundle (comprising the infraorbital nerve and artery) courses within the bony floor of the orbit; the roof of this infraorbital canal is only 0.23mm thick, and the bone of the posterior medial orbital floor averages 0.37 mm thick.
 - 4. By contrast, the bone of the lateral portion of the orbital floor averages 1.25 mm thick, over 5 times the thickness of the bone over the neurovascular bundle. As one might suspect, it is this very thin area of the orbital floor overlying the neurovascular bundle where isolated orbital floor fractures invariably occur.



130. Which of the following is endogenous pyrogen

a) PG E2

b) PG D2

c) PGF2 alpha

d) PG I2

Correct Answer - A

Answer: -A. PG E2

Pyrogen

- Pyrogens are substances that cause fever.
- Pyrogens may be exogenous or endogenous
- Exogenous → Bacterial toxins
- Endogenous → IL-1, TNF- α , IL-6, Interferons, Ciliary neurotrophic factor
- These pyrogens increase the level of PGE, in the hypothalamus that elevates the thermoregulatory set point and causes fever.

131. In Bartter syndrome defect is seen in:

a) Defect in PCT

b) Defect in DCT

c) Defect in thick ascending limb of loop of henle

d) None

Correct Answer - C

Answer: C - Defect in thick ascending limb of loop of henle

Autosomal recessive disorder.

Genetic defect in the thick ascending limb of the loop of henle

Defects in Na-K-2Cl/ co⁻transporter, K or Cl channels result in lack of concentrating ability

132. Not seen in allergic pulmonary aspergillosis is

- a) High IgE level
- b) Recurrent pneumonia
- c) Occurrence in patients with old cavitory lesions
- d) Pleural effusion

Correct Answer - B

Answer: B-Recurrent pneumonia

Allergic bronchopulmonary aspergillosis is a pulmonary hypersensitivity disorder caused by allergy to fungal antigens that colonize the tracheobronchial tree.

It most commonly occurs in atopic asthmatic individuals in response to antigen of aspergillus species.

Main diagnostic criteria

- Clinical history of Asthma Q
- Pulmonary infiltrates (transient /fleeting or fixed)Q
- Peripheral eosinophilia ($> 1000 /\mu\text{L}$)Q
- Immediate skin reactivity to Aspergillus antigen (wheal and flare response)
- Serum precipitins to A. fumigatus
- Elevated serum IgE levels($>100\text{Ong/ml}$)
- Central /proximal bronchiectasis

Secondary diagnostic criteria

- History of brownish plugs in sputum
- Identification / culture of A., fumigatus from sputum
- Late skin reactivity to aspergillus antigen - CMDT
- Elevated IgE (and IgG) class antibodies specific for A. fumigatus - Harrisons

Note

Elevated IgE (and IgG) class antibodies specific for *A. fumigatus* has been mentioned as a secondary diagnostic criteria in Harrison's textbook while Fishman's textbook includes this as a main/major diagnostic criteria.

133. Pseudo P Pulmonale

a) Hypokalemia

b) Hyponatremia

c) Hypocalcemia

d) Hypercalcemia

Correct Answer - A

Answer: A. Hypokalemia

In some cases there can be a notched (or bifid) p-wave known as “p mitrale”, indicative of left atrial hypertrophy which may be caused by mitral stenosis. There may be tall peaked p-waves. This is called “p-pulmonale” and is indicative of right atrial hypertrophy often secondary to tricuspid stenosis or pulmonary hypertension.

A similar picture can be seen in hypokalemia (known as “pseudo p-pulmonale”).

134. Automatic Implantable Cardioverter Defibrillator, (AICD) implantation is done for which of following conditions:

- a) Brugada syndrome
- b) Ventricular fibrillation
- c) Acute coronary syndrome with low EF
- d) All of the above

Correct Answer - D

Answer: D. All of the above

An Automatic Implantable Cardioverter Defibrillator, (AICD), is a small electronic device that is implanted into your chest to monitor and correct an abnormal heart rhythm, or arrhythmia. These devices are used to treat serious and life-threatening arrhythmias and are the most effective way of doing so.

Brugadasyndrome is a condition that causes a disruption of the heart's normal rhythm.

Ventricular fibrillation is a heart rhythm problem that occurs when the heart beats with rapid, erratic electrical impulse.

Acute coronary syndrome is a term used to describe a range of conditions associated with sudden, reduced blood flow to the heart.

135. What is the line of treatment for intractable Sydenham chorea?

a) Haloperidol

b) Valproate

c) Warfarin

d) Risperidone

Correct Answer - B

Answer: B. Valproate

Sydenham's chorea (SC) / Chorea minor / Rheumatic chorea (RC) / St. Vitus' s Dance

- Major diagnostic criteria for rheumatic disease
- Most common acquired chorea during childhood
- Characterized by rapid, uncoordinated jerking movements primarily affecting the face, hands and feet
- Benzodiazepines facilitate the action of GABA and valproate enhances the action on GABA, hence these agents are used to treat chorea

136. Neurofibromatosis 1 criteria except

a) Brain tumor

b) Acoustic neuromas

c) Pseudoarthrosis

d) Cafe-au-lait spots

Correct Answer - B

Answer: B - Acoustic neuromas

Clinical diagnosis requires presence of at least 2 of 7 criteria to confirm presence of neurofibromatosis, type 1.

Despite suspicion, most signs do not appear until late childhood / adolescent

The 7 clinical criteria used to diagnose NF1 are as follows:

- Six or more café-au-lait spots / hyperpigmented macules greater than or equal to 5 mm in diameter in prepubertal children & 15 mm postpubertal
- Axillary or inguinal freckles (>2)
- Two or more typical neurofibromas or one plexiform neurofibroma
- Optic nerve glioma
- Two or more iris hamartomas (Lisch nodules) (often identified only through slit-lamp examination)
- Sphenoid dysplasia or typical long-bone abnormalities such as pseudarthrosis
- Strong family history (1st degree relative with NF1)

137. Most common site of chronic gastric ulcer

- a) Pyloric antrum
- b) Upper part of lesser curvature
- c) Lower part of lesser curvature
- d) Segment of large intestine

Correct Answer - A

Answer: A - Pyloric antrum

A major causative factor (60% of **gastric** & up to 50–75% of duodenal **ulcers**) is chronic inflammation due to **Helicobacter pylori** that colonizes the **antral mucosa**.

138. Approximate time interval between HIV infection & manifestation of AIDS is?

a) 7.5 yr

b) 10 yr

c) 12 yr

d) 11 yr

Correct Answer - B

Answer: B - 10 years

The approximate time frame required for incubation is usually **10 years**.

median time from infection to the development of AIDS in adults is about 9 years. A small proportion of untreated HIV-infected people are long-term non-progressors, with CD4 counts in the reference range for 10 years or more. Some long-term non-progressors have undetectable viral loads and are known as 'elite controllers'.

139. Heller's myotomy is done for

a) Zenker's diverticulum

b) Achalasia cardia

c) Bunions

d) Knee arthroscopy

Correct Answer - B

Answer: B - Achalasia cardia

Achalasia, a disorder of esophagus characterized by progressive inability to swallow solids & liquids.

Causes include weakened esophageal muscles & issues with lower esophageal sphincter relaxation

Heller Myotomy, surgical procedure offers long term symptomatic relief to these patients.

It involves weakening of muscles at gastroesophageal junction, allowing the valve between oesophagus & stomach to remain open.

140. Myocardial stunning pattern not matching the ECG. What is the diagnosis.

a) Takotsubo cardiomyopathy

b) Restrictive cardiomyopathy

c) Brigade's cardiomyopathy

d) Pericardial something

Correct Answer - A

Answer: A -Takotsubo cardiomyopathy

“Myocardial Stunning” is a state where **certain segments of myocardium** (corresponding to area of major coronary occlusion) **shows forms of contractile abnormality**.

A segmental dysfunction persisting for a variable period of time, about two weeks, even after ischemia has been relieved (by for instance angioplasty or coronary artery bypass surgery).

Takotsubo cardiomyopathy / Takotsubo syndrome, a temporary condition where your heart muscle becomes suddenly weakened or 'stunned'.

141. Alternative drug for cardiac arrest in place of epinephrine is?

- a) Amiodarone infusion
- b) Atropine
- c) High dose vasopressin
- d) Adenosine

Correct Answer - C

Answer: C - High dose vasopressin

Vasopressin is an alternative vasopressor at high doses, causes vasoconstriction by directly stimulating smooth muscle V1 receptors.

American Heart Association (AHA) guidelines states "Vasopressin is a reasonable first-line vasopressor in patients with ventricular fibrillation or pulseless ventricular tachycardia. Additionally, the guidelines comment that one dose of vasopressin 40 U may replace the first or second dose of epinephrine in all pulseless sudden cardiac arrest scenarios, including asystole and pulseless electrical activity.

142. Patient presenting with cutaneous vasculitis, glomerulonephritis, peripheral neuropathy, Which investigation is to be performed next that will help you diagnose the condition?

a) ANCA

b) RA factor

c) Hbsag

d) MIF

Correct Answer - A

Answer: A - ANCA

Anti-neutrophil cytoplasmic antibodies (ANCAs):

- Group of autoantibodies
- IgG type mainly,
- Produced against antigens in cytoplasm of neutrophil granulocytes & monocytes.
- Particularly associated with systemic vasculitis, so called “ANCA-associated vasculitis”.

143. Cryoglobulinemia

a) Hepatitis c

b) Ovarian cancer

c) Diabetes

d) Leukemia

Correct Answer - A

Answer: A. Hepatitis C

Cryoglobulinemia / Cryoglobulinemic disease with large amounts of cryoglobulins in blood

Cryoglobulins are proteins (mostly immunoglobulins themselves)

Become insoluble at reduced temperatures.

Mixtures of monoclonal or polyclonal IgM, IgG, and/or IgA & blood complement proteins like C4 are associated with cases of infectious diseases, particularly Hepatitis C infection,

144. Causes of hypokalemic metabolic alkalosis with hypertension

- a) Liddle syndrome
- b) Bartter syndrome
- c) Gitelman syndrome
- d) Renal tubular acidosis

Correct Answer - A

Answer: A. Liddle syndrome

Liddle syndrome - Rare hereditary disorder

Increased activity of the epithelial sodium channel (E-Na Ch)

Activating kidneys to excrete potassium retaining excessive sodium & water, leading to hypertension.

145. Gold criteria for very severe COPD

a) $\text{Fev1/Fvc} < 70$ and $\text{Fev1} < 30$

b) $\text{Fev1/Fvc} < 70$ and $\text{Fev1} < 70$

c) $\text{Fev1/Fvc} < 70$ and $\text{Fev1} < 50$

d) Both A and C

Correct Answer - A

Answer: A. $\text{Fev1/Fvc} < 70$ and $\text{Fev1} < 30$

COPD should be considered in any patient who has dyspnea, chronic cough or sputum production, and/or a history of exposure to risk factors for the disease.

Spirometry is required to make the diagnosis.

Presence of post-bronchodilator $\text{FEV1/FVC} < 0.70$ confirms the presence of persistent airflow limitation.

Stage IV / Very Severe COPD

Severe airflow limitation ($\text{FEV1/FVC} < 70\%$; $\text{FEV1} < 30\%$ predicted) or $\text{FEV1} < 50\%$ predicted plus chronic respiratory failure.

Patients may have Very Severe (Stage IV) COPD even if FEV1 is $> 30\%$ predicted.

146. ABPI increases artificially in

a) Arteriosclerosis calcified arteries

b) Ischemic ulcers

c) Intermittent claudication

d) DVT

Correct Answer - A

Answer: A. Arteriosclerosis calcified arteries

The ankle-brachial pressure index (ABPI) / Ankle-Brachial index (ABI):

- Ratio of blood pressure at ankle to blood pressure in upper arm (brachium).
- Compared to arm, lower blood pressure in leg suggests blocked arteries due to peripheral artery disease (PAD).
- Ankle brachial pressure index (ABPI) is a method for the quantification of peripheral vascular disease that results from advanced atherosclerosis.

147. Minimal dysfunction syndrome seen in

a) Dyslexia

b) ADHD

c) Mental subnormality

d) Down's syndrome

Correct Answer - A

Answer: A. Dyslexia

Clinical feature of Minimal dysfunction syndrome includes dyslexia.

Minimal brain dysfunction:

- Neurodevelopmental disorder.
- Characterized by evidences of immaturity involving control of activity, emotions, & behavior
- Specific learning disabilities involving the communicating skills needed in reading, writing, and mathematics.
- Inability to maintain attention & concentration
- Inability to skillfully blend the auditory & visual functions essential in language performance

148. Van Nuys prognostic index is not based on:

a) Age

b) Microcalcification

c) Size

d) ER status

Correct Answer - D

Answer: D. ER status

DCIS may be classified using the Van Nuys system, which combines the

1. Patient's age,
2. Type of DCIS
3. Presence of microcalcification,
4. The extent of resection margin
5. The size of the disease.

Van Nuys Prognostic Index			
Parameter	Score 1	Score 2	Score 3
Van Nuys Classification	Group 1	Group 2	Group 3
	Non-high nuclear grade without necrosis	Non-High nuclear grade with necrosis	High nuclear grade with or without necrosis
Margins	≥10 mm	1–9 mm	
Size		16–40 mm	>40 mm
Age	>60	40–60	<40

149. Common cause of chronic pancreatitis

- a) Chronic alcohol
- b) Chronic pancreatic calculi
- c) pancreas divisum
- d) Gall bladder stones

Correct Answer - A

Answer: A. Chronic alcohol

"Worldwide, alcohol consumption and abuse is associated with chronic pancreatitis in up to 70% of cases "

150. The following statement about Keloid is true

- a) It contain growth factor
- b) Extended excision is the treatment of choice
- c) It do not extend beyond the wound
- d) None of the above

Correct Answer - A

Answer: A. It contain growth factor

Vaccinations, injections, insect bites, ear piercing, or may arise spontaneously.

Keloids tend to occur 3 months to years after the initial insult, and even minor injuries can result in large lesions.

They vary in size from a few millimeters to large, pedunculated lesions with a soft to rubbery or hard consistency.

Although they project above surrounding skin, they rarely extend into underlying subcutaneous tissues.

Certain body sites have a higher incidence of keloid formation, including the skin of the earlobe as well as the deltoid, presternal, and upper back regions.

They rarely occur on eyelids, genitalia, palms, soles, or across joints.

Keloids rarely involute spontaneously, whereas surgical intervention can lead to recurrence, often with a worse result.

151. Which of the following layers are cut during fasciotomy ?

a) Skin

b) Skin+subcutaneous fascia

c) Skin+subcutaneous tissue+Superficial fascia

d) Skin+subcutaneous tissue+Superficial fascia+deep fascia

Correct Answer - D

Answer: D. Skin+subcutaneous tissue+Superficial fascia+deep fascia

Fasciotomy or fasciectomy is a surgical procedure where complete opening of all fascial envelope is done to relieve tension or pressure commonly to treat the resulting loss of circulation to an area of tissue or muscle. Fasciotomy is a limb-saving procedure when used to treat acute compartment syndrome.

152. Which statement is not true regarding crohn's disease :

- a) Rectum is not involved
- b) Continuous lesion visualized in endoscopy
- c) Non caseating granulomas
- d) Cobblestone appearance

Correct Answer - B

Answer: B. Continuous lesion visualized in endoscopy

Crohn's disease is frequently associated with "skip lesions," **discontinuous areas of active disease in the colon** and small intestine with intervening segments that appear normal.

153. Which is the best investigation for carcinoma head of pancreas:

a) Guided biopsy

b) ERCP

c) Transduodenal/transperitoneal sampling

d) EUS

Correct Answer - D

Answer: D

Medical imaging techniques, such as computed tomography (CT scan) and endoscopic ultrasound (EUS) are used both to confirm the diagnosis and to help decide whether the tumor can be surgically removed

154. An abdominal mass is best demonstrated in congenital hypertrophic pyloric stenosis by:

a) In palpation over the epigastrium

b) In left hypochondriac

c) Right iliac fossa

d) During feeding

Correct Answer - D

Answer: D. During feeding

Congenital hypertrophic pyloric stenosis

Presentation

- Vomiting is the presenting symptom (child vomits milk and no bile is present)
- Immediately after vomiting the child is hungry i.e. loss of appetite does not occur.
- Weight loss is striking and rapidly the infant becomes emaciated and dehydrated.

However, greater awareness of pyloric stenosis has led to earlier identification of patients and hence with fewer incidences of chronic malnutrition and severe dehydration - Nelson 10th/1130

The diagnosis is usually made with a test feed: In this, the baby is fed with the bottle by a nurse or mother and surgeon :

- IHPS/CHPS can be diagnosed clinically. During a test feed, there is visible gastric peristalsis passing from left to right across the upper abdomen and in a relaxed baby, the pyloric 'tumor' is palpable as an 'olive' in the right upper quadrant.
- The diagnosis can be confirmed by an ultrasound, which shows

the thickened pyloric muscle.

**155. Calculate GCS of 25 year old head injury patient with following parameters
confused, opening eyes in response to
pain, localizing pain will be-**

a) 6

b) 11




c) 12

d) 7

Correct Answer - B

Answer: B. 11

Glasgow coma scale:

Behaviour	Response
 Eye Opening Response	4: Spontaneously 3: To speech 2: To pain 1: No response
 Verbal Response	5: Oriented to time, person and place 4: Confused 3: Inappropriate words 2: Incomprehensible sounds 1: No response
 Motor Response	6: Obeys command 5: Moves to localised pain 4: Flex to withdraw from pain 3: Abnormal flexion 2: Abnormal extension 1: No response

156. RET proto-oncogene is associated with the development of

a) Medullary carcinoma thyroid

b) Astrocytoma

c) Paraganglioma

d) Hurthle cell tumor thyroid

Correct Answer - A

Answer: A. Medullary carcinoma thyroid

RET proto-oncogene is a growth factor receptor (receptor tyrosine kinase)

The RET protein is a receptor for the glial cell line-derived neurotrophic factor and structurally related proteins that promote cell survival during neural development.

RET is normally expressed in the following cells

- Parafollicular C cells of the thyroid
- Adrenal medulla
- Medullary carcinoma may occur in combination with adrenal pheochromocytoma and hyperparathyroidism (HPT) (usually due to hyperplasia) in the syndrome known as multiple endocrine neoplasia type 2A (MEN-2A).
- These are tumors of the parafollicular (C cells) derived from the neural crest rather than the cells of the thyroid follicle as are other primary thyroid carcinomas
- When the familial form is associated with prominent mucosal neuromas involving the lips, tongue and inner aspect of the eyelids, with a Marfanoid habitus, the syndrome is referred to as MEN type 2B.
- RET associations: MEN 2a, MEN 2b, Familial medullary carcinoma

thyroid.

157. Cutoff for surgery in an abdominal aortic aneurysm in asymptomatic patients-

a) 5.5cm

b) 6.5cm

c) 7.5cm

d) 8.5cm

Correct Answer - A

Answer: A. 5.5cm

Operative repair of the aneurysm with the insertion of a prosthetic graft or endovascular placement of aortic stent graft is indicated for:

- Abdominal aortic aneurysms of any size that are expanding rapidly or are associated with symptoms.
- For asymptomatic aneurysms, abdominal aortic aneurysm repair is indicated if the diameter is >5.5 cm.

158. Which of the fontanelle is the last to close?

a) Anterolateral

b) Anterior

c) Lateral

d) Occipital

Correct Answer - B

Ans. B. Anterior

The posterior fontanelle normally closes 2 to 3 months after birth

The sphenoidal fontanelle is the next to close around 6 months after birth

The mastoid fontanelle closes next from 6 to 18 months after birth;

The anterior fontanelle is generally the last to close between 18–24 months.

159. Which enzyme deficiency causes Lesch–Nyhan syndrome ?

- a) Hypoxanthine-guanine phosphoribosyltransferase (HGPRT)
- b) Xanthine oxidase
- c) Adenine phosphoribosyltransferase (APRT)
- d) AMP deaminase

Correct Answer - A

Ans. A. Hypoxanthine-guanine phosphoribosyltransferase (HGPRT)

Lesch–Nyhan syndrome (LNS), also known as juvenile gout, is a rare inherited disorder caused by a deficiency of the enzyme hypoxanthine-guanine phosphoribosyltransferase (HGPRT), produced by mutations in the HPRT gene located on the X chromosome

160. Which vaccine is not include in indradhanush mission?

a) Tuberculosis

b) Measles

c) Japanese Encephalitis

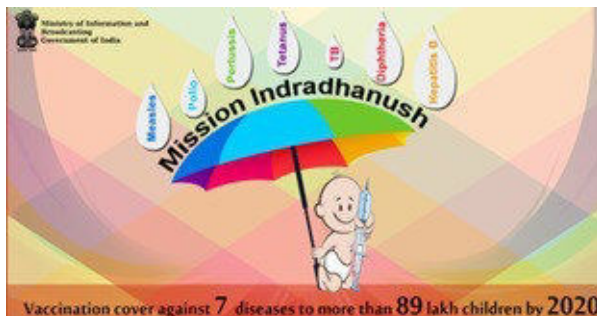d) Diphtheria

Correct Answer - C

Ans. C. Japanese Encephalitis

The Mission Indradhanush, depicting seven colours of the rainbow, targets to immunize all children against seven vaccine preventable diseases namely:

- Diphtheria
- Pertussis
- Tetanus
- Childhood Tuberculosis
- Polio
- Hepatitis B
- Measles.



161. Which among the following is the Most common cause for neonatal blindness?

a) *Neisseria gonorrhoeae*

b) *Chlamydia trachomatis*

c) *Klebsiella*

d) *Enterobacter*

Correct Answer - A

Ans. A. *Neisseria gonorrhoeae*

Ophthalmia neonatorum (ON) is defined as a purulent conjunctivitis occurring during the first four weeks of life.

The two most common causative agents are *Neisseria gonorrhoeae* and *Chlamydia trachomatis*, the former being of more concern here because of its propensity to cause blindness.

162. Muscles affected in De quervain tenosynovitis -

- a) Abductor pollicis longus and extensor pollicis brevis
- b) Adductor pollicis longus and extensor pollicis brevis
- c) Abductor pollicis longus and Flexor pollicis brevis
- d) Adductor pollicis longus and Flexor pollicis brevis

Correct Answer - A

Ans. A. Abductor pollicis longus and extensor pollicis brevis

De Quervain syndrome, is a tenosynovitis of the sheath or tunnel that surrounds two tendons that control movement of the thumb.

De Quervain syndrome involves non-inflammatory thickening of the tendons and the synovial sheaths that the tendons run through.

The two tendons concerned are those of the extensor pollicis brevis and abductor pollicis longus muscles.

163. What is meant by Perilunate dislocations ?

- a) Lower radius,scaphoid and lunate and capitate all in same plane
- b) Lower radius,scaphoid and capitate in alignment,lunate alone out of plane
- c) Lower radius,scaphoid and Lunate in alignment ,capitate alone is out of plane
- d) Both lunate and capitate are out of plane

Correct Answer - B

Ans. B.Lower radius,scaphoid and capitate in alignment,lunate alone out of plane

Perilunate dislocation and perilunate fracture dislocation are injuries that involve traumatic rupture of the radioscapnocapitate (RSC) ligament, the scapholunate interosseous ligament, and the lunotriquetral interosseous ligament.

Lateral radiographs will reveal loss of collinearity between the capitate, lunate, and radius

Typically the capitate is located dorsal to the lunate and is aligned with the radius

164. Fallen fragment sign -

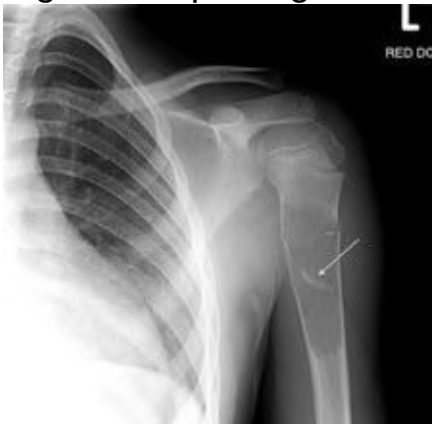- a) Simple bone cyst
- b) Osteosarcoma
- c) Adamantinoma
- d) Aneurysmal bone cyst

Correct Answer - A

Ans. A. Simple bone cyst

The fallen fragment sign refers to the presence of a bone fracture fragment resting dependently in a cystic bone lesion. This finding is said to be pathognomonic for a simple (unicameral) bone cyst following a pathological fracture.

Although it has occasionally been reported with other cystic lesions, e.g. eosinophilic granuloma



165. You are posted as an intern in casualty. Which among the following patients with fracture will be your 1st priority to call ortho PG and inform?

- a) Patient's finger is blackening
- b) Patient can't extend his arm
- c) A 10 cm abrasion
- d) Intra articular fracture of Elbow Joint

Correct Answer - A

Ans. A. Patient's finger is blackening

Blackening of finger after Fracture is an indication of cut of blood supply that may lead to severe complication like gangrene. So this should be the first Priority to treat among all the above options

166. In Rheumatoid arthritis, which type of cells are prominently present ?

a) B cells

b) T cells

c) Macrophages

d) Dendritic cells

Correct Answer - C

Ans. C. Macrophages

Synovial lining or intimal layer: Normally, this layer is only 1-3 cells thick. In RA, this lining is greatly hypertrophied (8-10 cells thick).

Primary cell populations in this layer are fibroblasts and macrophages.

167. 8th and 9th rib costal cartilage forms which type of joint?

a) Costochondral joint

b) Interchondral joint

c) Synovial joint

d) Costovertebral joint

Correct Answer - C

Ans. C. Synovial joint

The sixth, seventh, eighth, ninth and tenth costal cartilages are jointed with each other along the borders by synovial joints. Costochondral joint means the joint between the rib and its costal cartilage.

The first costal cartilage of both sides attach to the manubrium sterni. At this joint, no movement is possible.

The second costal cartilage articulates with the body of sternum and the manubrium sterni by a synovial joint where movement is possible.

The third to seventh costal cartilages articulate with lateral border of the body of sternum at mobile synovial joints.

168. Tom smith septic arthritis is-

a) Acute Gonococcal arthritis

b) Smallpox arthritis

c) Septic arthritis of infancy

d) Chronic pyogenic arthritis

Correct Answer - C

Ans. C. Septic arthritis of infancy

Septic arthritis of infancy (Tom smith septic arthritis)

It is a septic arthritis of hip seen in infants

The onset is acute with rapid abscess formation, which may burst out or be incised and heals rapidly.

Telescope test is positive

Clinically this condition resembles a congenital dislocation of hip

169. Which of the following is correct regarding placenta?

- a) Placental artery provides nutrients through umbilical cord to baby
- b) Placenta has Wharton's jelly
- c) Placenta has 2 veins and 1 artery
- d) Estrogen is secreted by placenta

Correct Answer - B

Ans. B. Placenta has Wharton's jelly

The umbilical cord is a structure that provides vascular flow between the fetus and the placenta.

It contains two arteries and one vein, which are surrounded and supported by gelatinous tissue known as Wharton's jelly.

170. Acute fatty liver commonly seen in pregnancy at-

a) 3rd trimester

b) 1st trimester

c) Immediate postpartum

d) Intrapartum

Correct Answer - A

Ans. A. 3rd trimester

Acute fatty liver of pregnancy (AFLP) is a rare, potentially fatal complication that occurs in the third trimester or early postpartum period.

Acute fatty liver of pregnancy is more commonly associated with:

- Male fetus
- First pregnancy
- Maternal obesity

It is due to defect in the long-chain-3-hydroxyacyl-CoA-dehydrogenase pathway.

It is uncommon in subsequent pregnancies.

171. Establishment of fetoplacental circulation seen at-

a) 11 to 13 days

b) 20 to 22 days

c) 7 days

d) 25 to 26 days

Correct Answer - B

Ans. B.20 to 22 days

Important Events Following Fertilization

0' hour	Fertilization (day-15 from LMP)
30 hours	2 cell stage (blastomeres)
40–50 hours	4 cell stage
72 hours	12 cell stage
96 hours	16 cell stage. Morula enters the uterine cavity
5th day	Blastocyst
4–5th day	Zona pellucida disappears
5–6th day	Blastocyst attachment to endometrial surface
6–7th day	Differentiation of cyto and syncytiotrophoblast layers
10th day	Synthesis of hCG by syncytiotrophoblast
9–10th day	Lacunar network forms
10–11th day	<ul style="list-style-type: none"> • Trophoblasts invade endometrial sinusoids establishing uteroplacental circulation • Interstitial implantation completed with entire decidual coverage
13th day	Primary villi
16th day	Secondary villi

Primary villi	Secondary villi
21st day	Tertiary villi
21st–22nd day	Fetal heart. Fetoplacental circulation

172. Fimbriectomy procedure is known as-

a) Uchida method

b) Irving method

c) Madlener technique

d) Kroener method

Correct Answer - D

Ans. D. Kroener method

Uchida technique—A saline solution is injected subserosal in the mid portion of the tube to create a bleb.

Irving method — The tube is ligated on either side and mid portion of the tube (between the ties) is excised.

Madlener technique -It is the easiest method. The loop of the tube is crushed with an artery forceps.

Kroener method of fimbriectomy is not a common procedure

173. RDA of iodine in lactation in microgram-

a) 150

b) 220

c) 100

d) 250

Correct Answer - D

Ans. D. 250

To accommodate increased iodine needs during pregnancy and lactation, the iodine RDA is 220 mcg/day for pregnant women and 250 mcg/day for lactating women

174. Which One of the following is not a cause of secondary Postpartum Haemorrhage?

a) Placenta previa

b) Retained bits of placenta

c) Endometritis

d) Polyp

Correct Answer - A

Ans. A.Placenta previa

Causes of secondary Postpartum Haemorrhage are:

- Retained bits of placenta
- Postpartum infection
- Infection of Cervical and Vaginal Tears
- Puerperal Inversion of Uterus
- Uterine Polyp or Fibroid:
- Undiagnosed carcinoma of cervix
- Chorion-epithelioma

175. Best time to do quadruple test

a) 8-12 weeks

b) 11-15 weeks

c) 15-20 weeks

d) 18-22 weeks

Correct Answer - C

Ans. C.15-20 weeks

The quad screen is done in the second trimester, usually between 15 and 20 weeks of pregnancy.

Ideally, the test should be performed in conjunction with first-trimester screening tests.

176. Drug that is used for fetal lung maturity is:

a) Dexamethasone

b) Folic acid

c) Beclomethasone

d) None

Correct Answer - A

Ans. A. Dexamethasone

Betamethasone and dexamethasone are corticosteroids, also called glucocorticoids, that are given before birth (antenatally) to speed up a preterm fetuses lung development.

Either is used when a mother is in preterm labor and birth may occur in 24 to 48 hours.

177. In Uterine prolapse how to know if ring is in place?

- a) If not expelled after increased abdominal pressure
- b) If Bleeding does not occur
- c) If patient feels discomfort
- d) None

Correct Answer - A

Ans. A.If not expelled after increased abdominal pressure

A vaginal pessary is a removable device placed into the vagina. It is designed to support areas of pelvic organ prolapse.

A variety of pessaries are available, including the ring pessaries. If not expelled after increased abdominal pressure, the ring pessary is supposed to be placed in place.

178. HT indicated in menopausal women

a) Hot flash

b) Ca breast

c) Endometriosis

d) Uterine bleeding

Correct Answer - A

Ans. A. Hot flash

Hormone Therapy (HT) is one of the government-approved treatments for relief of menopausal symptoms.

These symptoms, caused by lower levels of estrogen at menopause, include :

- Hot flashes,
- Sleep disturbances, and
- Vaginal dryness.
- HT is also approved for the prevention of osteoporosis.

179. Dilatation & curettage (D&C) is contraindicated in-

a) Pelvic inflammatory disease (PID)

b) Endometriosis

c) Ectopic pregnancy

d) None

Correct Answer - A

Ans. A. Pelvic inflammatory disease (PID)

Predisposing risk factors for PID are:

- Sexual contact
- History of STI

Procedures involving the upper female genital tract including:

- Dilatation & curettage (D&C)
- Recent intrauterine device (IUD) insertion
- Therapeutic abortion (T/A)

180. Which of these steps is followed first for the management of shoulder dystocia after McRoberts maneuver?

a) Sharp flexion of hip joints towards abdomen

b) Supra pubic pressure

c) 90 degree rotation of posterior shoulder

d) Emergency c-section

Correct Answer - B

Ans. B. Supra pubic pressure

Applying a gentle suprapubic pressure is the first step in management of shoulder dystocia after McRoberts maneuver.

Mnemonic “HELPERR” as a guide for treating shoulder dystocia:

- “H” stands for help
- “E” stands for evaluate for episiotomy.
- “L” stands for legs (pull your legs toward your stomach McRoberts maneuver)
- “P” stands for suprapubic pressure
- “E” stands for enter maneuvers (internal rotation of baby’s shoulders)
- “R” stands for remove the posterior arm from the birth canal.
- “R” stands for roll the patient.

181. True hermaphroditism karyotype:

a) 45 X0 streaked gonads

b) 46 XX Ovotestis

c) 47 XY+9

d) 47 XX

Correct Answer - B

Ans. B.46XX Ovotestis

True hermaphrodite or ovotesticular disorder of sexual differentiation (OVO-DSD) is one of the rarest variety of all inter sex anomalies.

In about 90% of cases, patients have 46 XX karyotype.

Rarely, 46 XY/46 XX mosaicism may occur.

182. Peripartum cardiomyopathy occurs at-

a) Within 7 days

b) Within 6 weeks

c) Within 24 months

d) Within 5 months

Correct Answer - D

Ans. D. Within 5 months

PPCM is a structural heart muscle disease that **occurs** in women either at the end of pregnancy or up to five months after giving birth.

Pearson's diagnostic criteria for peripartum cardiomyopathy:

- Development of cardiac failure in the last month of pregnancy or within 5 months after delivery
- Absence of an identifiable cause for the cardiac failure
- Absence of recognizable heart disease prior to the last month of pregnancy, and
- Left ventricular systolic dysfunction demonstrated by classic echocardiographic criteria, such as depressed ejection fraction or fractional shortening along with a dilated left ventricle.

183. Nerve mostly compressed in pregnancy puerperium:

a) Radial nerve

b) Median nerve

c) Femoral nerve

d) Facial nerve

Correct Answer - C

Ans C. Femoral nerve

The most common postpartum nerve injury is foot drop due to injury to the peroneal nerve and injury to the lateral femoral cutaneous nerve.

Obstetricians may consider frequent position changes in labor, avoidance of prolonged hip flexion, and shortening the pushing time by allowing for passive descent of the fetus before pushing begins as means of avoiding lateral femoral cutaneous nerve injury.

184. In pregnancy which of the following level is altered mostly:

a) Total T3

b) Free T3

c) Free T4

d) TSH

Correct Answer - A

Ans A. Total T3

Total T3 levels are altered throughout pregnancy.

Hormones during pregnancy:

Increased

Growth Hormone

Prolactin

Total T3, Total T4

Aldosterone

Testosterone, Androstenedione
and cortisol

Insulin (due to insulin resistance)

Estrogen

Progesterone

Total T3 and total T4 increase due to stimulation of thyroid tissue by hCG during the early period of gestation. But there is no change in free T3 and T4 due to increase in TBG.

This leads to transient fall in TSH during an early weeks of gestation.

Decreased

Luteinizing hormone

Follicle-stimulating
hormone

Di-Hydro

EpiAndroSterone

Unchanged

ADH

Free
T3, Free T4

The level of TSH reaches normal level during second and third trimester.

185. Paget's is associated with which other cancer:

a) Vulva

b) Vagina

c) Cervix

d) Uterus

Correct Answer - A

Ans. A. Vulva

Extramammary Paget's disease (EMPD), also extramammary Paget disease, is a rare, slow-growing, usually noninvasive intraepithelial (in the skin) adenocarcinoma outside the mammary gland and includes Paget's disease of the vulva and the extremely rare Paget's disease of the penis.

186. What is meant by Superfecundation?

- a) Fertilization of two or more ova in one intercourse
- b) Fertilization of two or more ova in different intercourses in same menstrual cycle
- c) Fertilization of ova and then it's division
- d) Fertilization of second ovum first being implanted

Correct Answer - B

Ans. B. Fertilization of two or more ova in different intercourses in same menstrual cycle

Superfecundation is the fertilization of two or more ova from the same cycle by sperm from separate acts of sexual intercourse, which can lead to twin babies from two separate biological fathers. The term superfecundation is derived from fecund, meaning the ability to produce offspring.

187. Fetal heart starts contracting at-

a) 10-12 days

b) 10-12 weeks

c) 3-5 weeks

d) 3- 5 month

Correct Answer - C

Ans. C 3-5 weeks

The fetal heart starts contracting at approximately 23 days of gestation.

188.

Anesthesia of choice for cesarean section in severe pre-eclampsia :

a) Spinal

b) GA

c) Epidural

d) Spinal+epidural

Correct Answer - C

Ans. C. Epidural

Continuous Epidural Anesthesia is the first choice for patients with preeclampsia during labour, Vaginal delivery and cesarean section. Preeclampsia patients have a risk of severe airway edema , which makes intubation difficult

Continuous Epidural Anesthesia can improve uteroplacental perfusion and also decrease catecholamine secretions.

189. Which of the following is not a high-risk pregnancy?

a) Previous history of manual removal of placenta

b) Anemia

c) Diabetes

d) Obesity

Correct Answer - A

Ans. A. Previous history of manual removal of placenta

High Risk Pregnancy is seen in :

Cardiovascular and renal factors:

- Moderate to severe preeclampsia
- Chronic hypertension
- Severe heart failure (class II-IV, NYHA classification)
- Moderate to severe renal disorders

Metabolic disorders:

- Obesity
- Insulin-dependent diabetes
- Previous endocrine ablation

Obstetric history:

- Fetal exchange transfusion because of Rh incompatibility
- Stillbirth
- Late abortion (16–20 wk)
- Post-term pregnancy (> 42 wk)
- Preterm newborn (< 37 wk and < 2500 g)
- Intrauterine growth restriction (weight < 10th percentile for estimated gestational age)
- Polyhydramnios
- Multifetal pregnancy

- Previous brachial plexus injury
- Abnormal fetal position
- Other disorders:
 - Abnormal cervical cytologic findings
 - Sickle cell disease
 - Severe anemia
 - Thrombophilia
 - Autoimmune disorders
- Anatomic abnormalities:
 - Uterine malformation
 - Insufficient (incompetent) cervix
- Exposure to teratogens:
 - Group B streptococcal infections
 - Smoking > 10 cigarettes/day (associated with premature rupture of membranes)
- Current pregnancy complications:
 - Preterm labor at < 37 Wks
 - Preterm premature rupture of membranes
 - Moderate to severe preeclampsia
 - Polyhydramnios (hydramnios) or oligohydramnios
 - Post-term (> 42 wk)
 - Uterine rupture
 - Placenta previa
 - Abruptio placentae
 - Chorioamnionitis
 - Prolapsed cord
 - Fetal bradycardia for >30 min
 - Fetal tachycardia for >30 min
 - Fetal weight < 2.5 kg
 - Fetal weight > 4 kg
 - Fetal acidosis pH ≤ 7

190. Which of the following is not used in preeclampsia?

a) Methyldopa

b) Atenolol

c) Labetalol

d) Hydralazine

Correct Answer - B

Ans. B. Atenolol

Choice of anti-hypertensives in pregnancy

- PIH / pre-eclampsia / severe pre-eclampsia : Labetalol
- Acute Hypertension/Hypertension crisis : IV labetalol > Nifedipine > Hydralazine
- Chronic Hypertension in pregnancy : Labetalol > Methyl dopa.

191. Cutis marmorata occurs due to exposure to –

a) Cold temperature

b) Dust

c) Hot temperature

d) Humidity

Correct Answer - A

Ans. A.Cold temperature

Cutis marmorata is a condition where in the skin has a pinkish blue mottled or marbled appearance when subjected to cold temperatures.

It is seen throughout infancy and in 50 % of children.

Rewarming restores the skin to normal.

It is caused by superficial small blood vessels in the skin dilating and contracting at the same time .

192. Murphy's eye is seen in -

a) Macintosh laryngoscope

b) Endotracheal tube

c) LMA

d) Flexible laryngoscope

Correct Answer - B

Answer: B - Endotracheal Tube

The "Murphy eye" is the eponymous name for a hole on the side of most endotracheal tubes (ETTs) that functions as a vent, and prevents the complete obstruction of the patient's airway, should the primary distal opening of an ETT become occluded

193. Modified Mallampati grading is used in assessment of -

- a) Difficult intubation
- b) Airway obstruction
- c) Death due to aspiration
- d) Intubation

Correct Answer - A

Answer: A - Difficulty in intubation

Modified Mallampati classification

- **Class 0:** Ability to see any part of the epiglottis upon mouth opening and tongue protrusion
- **Class I:** Soft palate, fauces, uvula, pillars visible
- **Class II:** Soft palate, fauces, uvula visible
- **Class III:** Soft palate, base of uvula visible
- **Class IV:** Soft palate not visible at all
- **Test:** The assessment is performed with the patient sitting up straight, mouth open and tongue maximally protruded, without speaking or saying "ahh."
- **Difficult laryngoscopy:** Good accuracy (area under Summary Receiver Operating Characteristic [SROC] curve 0.89 ± 0.05)
- **Difficult intubation:** Good accuracy (area under SROC curve 0.83 ± 0.03)
- **Difficult mask ventilation:** Poor predictor
- Used alone, the Mallampati tests have limited accuracy for predicting the difficult airway and thus are not useful screening tests
- Mallampati classification is only one of 11 nonreassuring findings during airway examination

194. Which nerve is tested for adequacy of anaesthesia -

a) Median Nerve

b) Ulnar Nerve

c) Radial nerve

d) Mandibular nerve

Correct Answer - A

Answer: A - Median nerve

Median nerve block can be evaluated by testing the lateral aspect of the ring finger

195. Most effective circuit in spontaneous anaesthesia is -

a) Mapleson A

b) Mapleson B

c) Mapleson C

d) Mapleson D

Correct Answer - A

Answer: A - Mapleson A

MAPLESON A - (Magill) CIRCUIT

Useful in spontaneous ventilation

- The patient inspires whatever is in the tube, using the bag as a volume reservoir.
- On exhaled tube and incoming fresh gas. When the bag is full, exhaled alveolar gas is vented during expiration, the bag refills from a combination of expired gas going back up the corrugated tube and the exhale valve, and then during any expiratory pause, FGF pushes the remaining alveolar gas out.
- Theoretically $FGF = 0.7 \times V_{\text{t}}$ should prevent significant rebreathing because deadspace gas (fresh) is not wasted, but $FGF = V_A$ more reliably prevents rebreathing.
- Tube volume must exceed $(V_t - V_d)$ or alveolar gas could contaminate the bag.
- Inadequate FGF causes rebreathing. Difficult to detect from the CO_2 waveform alone - all that happens is that the rapid fall on inspiration is delayed. If V_A exceeds tubing volume, CO_2 enters the bag and will be seen on inspiration on the capnogram.

Controlled ventilation

- If the anaesthetist fully closed the valve while squeezing the bag and

didn't open it until just before the bag filled, this circuit would be OK. More commonly the valve is partially closed - enough to permit adequate tidal volumes despite parallel loss of gas out the valve. FGF must be increased to compensate for gas lost during inspiration - typically 2.5x minute ventilation.

The Lack system

- A co-axial Magill, with the expiratory valve brought coaxially back to the Fresh Gas outlet. Not popular due to inefficiency during controlled ventilation.

196. What is mechanism of action of Curanium drugs as muscle relaxant?

- a) Persistently depolarizing at Neuromuscular junction
- b) Act competitively on Ach receptors blocking post-synaptically
- c) Repetitive stimulation of Ach receptors on muscle end plate
- d) Inhibiting the calcium channel on presynaptic membrane

Correct Answer - B

Answer: B - Act competitively on Ach receptors blocking post-synaptically

Candocuronium iodide is an aminosteroid neuromuscular-blocking drug or skeletal muscle relaxant in the category of non-depolarizing neuromuscular-blocking drugs.

Acts on Ach receptors competitively post-synaptically blocking them. Potential adjunctive use in anaesthesia to facilitate endotracheal intubation & provide skeletal muscle relaxation.

Candocuronium demonstrated a short duration and a rapid onset of action, with little or no ganglion blocking activity, and it was only slightly less potent than pancuronium

197. Dye used in diagnosis of esophageal perforation:

a) Iohexol

b) Barium sulphate

c) Gadolinium

d) Iodine dye

Correct Answer - B

Answer-B. Barium sulphate

Barium sulfate in suspension is frequently used medically as a radiocontrast agent for X-ray imaging and other diagnostic procedures.

It is most often used in imaging of the GI tract during what is colloquially known as a "barium meal".

Fluoroscopy

- most sensitive within the first 24 hours.
- patient examined semi-supine (~20 degrees) on fluoroscopy table
- a water-soluble agent should be used initially as **barium** can cause mediastinitis
- esophageal perforation may be represented as mucosal irregularity or gross extraluminal contrast extravasation
- some authors suggest the use of small amounts of low or high concentrations of barium if no leak is evident on initial screening with water soluble contrast

Iohexol, trade names **Omnipaque** among others, is a contrast agent used during X-rays. This includes when visualizing arteries, veins, ventricles of the brain, the urinary system, and joints, as well as during computer tomography. It is given by mouth, injection into a vein, or into a body cavity.

198. Bragg peak effect pronounced in:

a) X ray

b) Proton

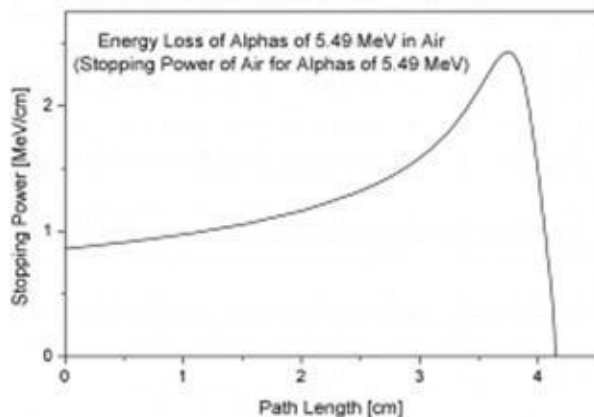
c) Neutron

d) Electron

Correct Answer - B

Answer- B. Proton

- Nowadays proton therapy (PT) represents an established alternative to photon radiotherapy for the treatment of specific types of cancer.
- The therapeutic use of proton beams (and of charged particles in general) is motivated primarily by their inverted depth-dose profile compared to photons, being characterized by the so-called Bragg peak.
- Several beams of different energy can then be combined in order to achieve the prescribed dose in a region as large as the target volume, resulting in the production of what is defined as the Spread-Out Bragg Peak (SOBP).



199. Salt and Pepper pot appearance of skull seen in:

- a) Hyperparathyroidism
- b) Multiple myeloma
- c) Hyperthyroidism
- d) Pseudo hyperparathyroidism

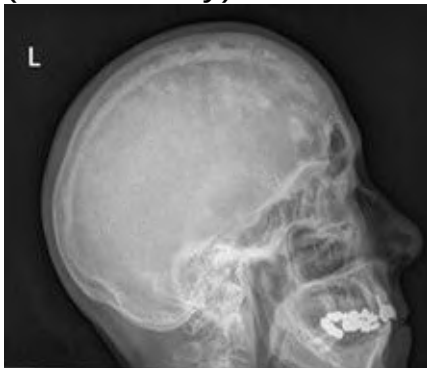Correct Answer - A

Answer- A. Hyperparathyroidism

Pepperpot skull is occasionally used in place of [salt and pepper skull](#) to describe the typical radiographic appearance of multiple small radiolucent lesions of the skull vault.

In **primary hyperparathyroidism**, extensive resorption bone in the skull in combination with cystic areas of osteopenia are termed **pepper pot skull**.

Classically seen in [hyperparathyroidism](#), and is occasionally used (inaccurately) to describe the [raindrop skull](#) of [multiple myeloma](#).



: Skull X-ray with a typical "pepper-pot" appearance

200. Imaging techniques used in Uterus anomalies EXCEPT:

a) HSG

b) MRI guided HSG

c) CT guided HSG

d) USG

Correct Answer - C

Answer C. CT guided HSG

Imaging studies, such as a **hysterosalpingogram (HSG)** and **ultrasound**, or an **MRI** are required to visualise the uterus and confirm that a congenital uterine anomaly is present. A hysterosalpingogram is not considered as useful due to the inability of the technique to evaluate the exterior contour of the uterus and distinguish between a bicornuate and septate uterus. In addition, [laparoscopy](#) and/or [hysteroscopy](#) may be indicated.

201. Semen squeeze

- a) Erectile dysfunction
- b) Premature ejaculation
- c) Retrograde ejaculation
- d) Antegrade ejaculation

Correct Answer - B

Answer: B- Premature Ejaculation

Squeeze Technique:

- Variation of the Masters and Johnson method.
- As a man approaches climax, either he or his partner squeezes the tip of the penis just below the head of the penis as he approaches the point of climax.
- Pressure is held there until the sensation of impending orgasm diminishes.
- This pressure can even be held until there is some reduction in erection.
- The process can then be started over again so that over time a man prolongs the time period until he reaches ejaculation.
- Useful to treat cases of premature ejaculation

202. A patient with a history of RTA before 2 months presents with complaints of dreams of accidents. He is able to visualize the same scene whenever he visits the place. Hence is afraid to go back to the accident site. Identify the type of disorder that he might be suffering from?

a) Adjustment disorder

b) PTSD

c) Anxiety disorder

d) OCD

Correct Answer - B

Answer: B - Post-traumatic Stress disorder

Post-traumatic stress disorder, basically a type of anxiety disorder

- Though it shares features with other anxiety disorders, has its own specific characteristics in presentation.
Criteria 1:
- Etiologically significant trauma should be present to be classified under this condition.
Criteria 2:
- “Intentionality” or “aboutness”, an important factor in PTSD.
- PTSD concerns with memory intrusion of past stressors into present.
- Nightmares, flashbacks, or reliving experiences should be related to

the past experience.

Criteria 3:

- Avoid a stimulus or activity that provokes the memory of past event.

203. Freud's theory of dream includes all except:

a) Displacement

b) Condensation

c) Symbolisation

d) Correlation

Correct Answer - D

Answer: -D - Correlation

Sigmund Freud theory of dream:

- Dream work involves the process of condensation, displacement, and secondary elaboration.

Concept of unconscious mind:

- Primary assumption of Freudian theory is that the unconscious mind governs behavior to a greater degree than people suspect.
- Goal of psychoanalysis is to make the unconscious, conscious.

Theory of dream:

- Freud theory of dream elaborates the state of unconscious mind with respect to dream interpretation,
- Process involved include condensation, displacement, and secondary elaboration.
- Displacement takes place when we transform the person or object we are really concerned about to someone else.
- The process of condensation is the joining of two or more ideas/images into one.

204. Expression and consequent release of previously repressed emotion is called as

a) Regression

b) Dissociation

c) Abreaction

d) All of the above

Correct Answer - C

Answer: C - Abreaction

The expression and consequent release of a previously repressed emotion, achieved through reliving the experience that caused it.

Done typically through

Hypnosis

Suggestion

205. All are habit disorder except

a) Nail biting

b) Thumb sucking

c) Temper tantrum

d) Tics

Correct Answer - C

Answer: C- Temper tantrum

Definition:

- Habit disorder is a term used to describe several related disorders linked by the presence of repetitive and relatively stable behaviour that seem to occur beyond the awareness of the person performing the behaviour.
- The first group of habit disorder includes "Tic Disorder"
- Tics are involuntary movements, sounds, or words that are sudden, rapid, recurrent and non-rhythmic"
- In addition to TD's, body-focussed behaviours,
- Recurrent hair pulling - Trichotillomania (TTM)
- Skin picking (SP)
- Nail biting , are included within habit disorders.

Head banging, rocking of body, teeth grinding & thumb sucking are repetitive disorders.

- Seen in children between age group of 6 months to 2 years.
- Benign & self-limited.
- The movements serve a means of tension discharging in children.
- As children become older, they learn to inhibit some of their rhythmic patterns.
- Undue attention by parents can lead to aggravation of these problems.

206. New name of mental retardation according to American Association of Mental Retardation

a) Feeble Mindedness

b) Madness

c) Intellectual disability

d) Mentally unstable

Correct Answer - C

Answer: C - Intellectual disability

Intellectual disability (ID), also known as general learning disability, Mental retardation (MR), is a generalized neurodevelopmental disorder characterized by significantly impaired intellectual and adaptive functioning.

207. Now-a-days Down syndrome is referred to as.

a) Submental disorder

b) Oligophrenia

c) Madness

d) Mentally unstable

Correct Answer - A

Answer: A - Submental disorder

Majority of children with Down syndrome function in mild to moderate range of mental retardation.

Down syndrome / Trisomy 21 -

- Genetic disorder caused by presence of all or part of a third copy of chromosome 21.
- Typically associated with physical growth delays, characteristic facial features and mild to moderate intellectual disability.

208. A 55 years aged chronic alcoholic male, presented with irrelevant talks, tremor and sweating. He had his last drink 3 days back. What will the probable diagnosis?

a) Delirium tremens

b) Korsakoff psychosis

c) Post-Acute withdrawal syndrome

d) Discontinuation syndrome

Correct Answer - A

Answer: A - Delirium Tremens

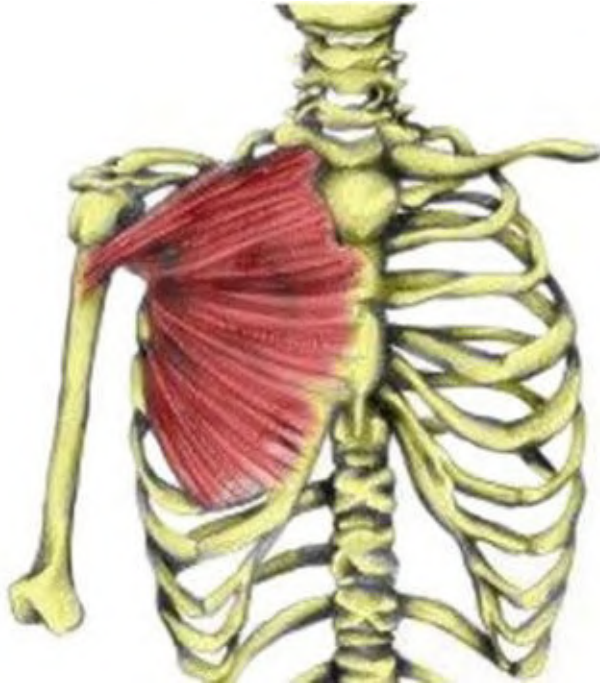The description of symptoms is related to the condition "Delirium Tremens"

Delirium Tremens / Alcohol Withdrawal Delirium (AWD):

- Most severe form of ethanol withdrawal manifested by,
 - **Altered mental status** (Global confusion)
 - **Autonomic hyperactivity** (Sympathetic overdrive)
- Mechanism:**
- Alcohol abuse affects neurotransmitter systems in brain mainly by,
 - **Loss of GABA inhibitory mechanism** - Reduces chloride ion influx.
 - Alcohol acts as NMDA receptor antagonist - **Withdrawal increases the excitatory neurotransmitter.**
 - The clinical manifestations of ethanol withdrawal are **combination effects of GABA & NMDA receptor activity.**
 - Thus causing **tremors, diaphoresis, tachycardia, anxiety & in**

severe cases Seizure.

209. Identify the type of muscle shown in the image below.



a) Cruciate

b) Multipennate

c) Parallel

d) Unipennate

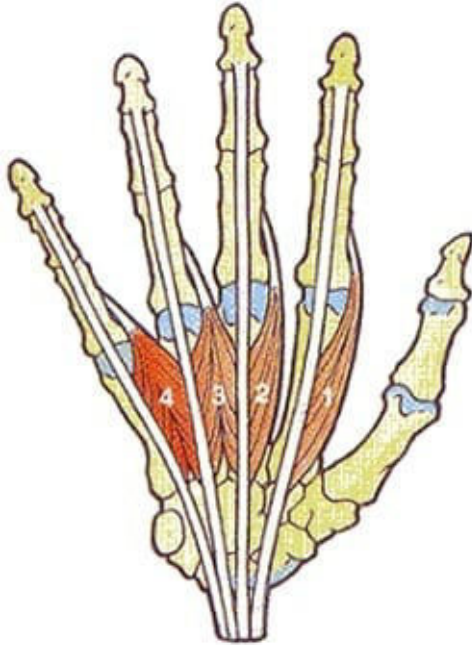
Correct Answer - B

Answer - B. Multipennate

The muscle depicted above is the pectoralis major.

Pectoralis Major has multiple rows of diagonal fibres with a single tendon, Hence is a multipennate muscle.

210. Function of the muscle shown in picture:



a) Flexion

b) Extension

c) Adduction

d) Abduction

Correct Answer - A

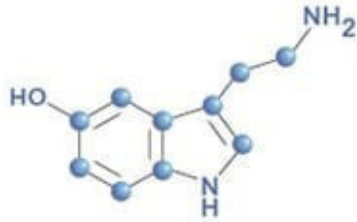
Answer- A. Flexion

Lumbricals are four short hand muscles located in the metacarpus deep to the palmar fascia.

The **lumbricals** are intrinsic muscles of the hand that **flex** the metacarpophalangeal joints and **extend** the interphalangeal joints.

The lumbricals are used during an upstroke in writing.

211. Following image is also known as?



a) 5-hydroxytryptamine (5-HT)

b) N-methyl phenylamine

c) 3-Methoxytyramine

d) Phenethylamine

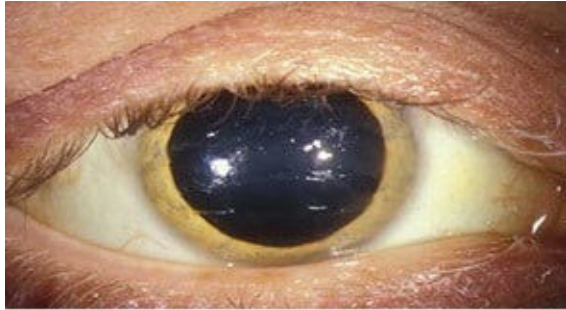Correct Answer - A

Ans: A. 5-hydroxytryptamine (5-HT)

Serotonin/ 5-hydroxytryptamine (5-HT) is a monoamine neurotransmitter.

Following hydroxylation of tryptophan to 5-hydroxytryptophan by liver tryptophan hydroxylase, subsequent decarboxylation forms serotonin (5-hydroxytryptamine), a potent vasoconstrictor and stimulator of smooth muscle contraction.

212. Choose the best method of diagnosis for the clinical sign represented in the image.



a) Serum copper

b) Serum ceruloplasmin

c) Karyotyping

d) PCR

Correct Answer - B

Answer: B - Serum Ceruloplasmin

Image represents "Kayser-Fleischer" ring

KF ring is golden brown ring due to deposition of copper in Descemet's membrane of cornea.

Clinical feature of "**Wilson's disease**"

Wilson's Disease:

- Rare autosomal recessive disease.
- Characterized by abnormal copper metabolism

Ophthalmic presentation:

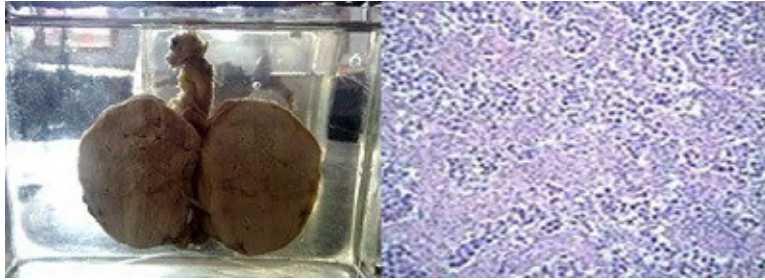
- Deposition of copper in posterior capsule of lens results in sunflower cataract.

Diagnosis:

Sternlieb's criteria:

- Presence of KF rings
 - Decreased serum ceruloplasmin (copper containing enzyme / ferroxidase) levels
 - Measuring hepatic copper levels in liver biopsy
 - 24-Hr urine copper excretion
- Kayser Fleischer ring:**
- Excess circulating copper deposits in descemet's membrane.
 - Usually golden brown located in peripheral cornea, beginning at schwalbe's line upto 5 mm into cornea.
 - Detected via Gonioscopy in earlier stage & seen by naked eyes in advanced stage.

213. Identify the condition represented in the image.



a) Seminoma

b) Germ cell differentiate tumor

c) Non-seminoma

d) Teratoma

Correct Answer - A

Answer: A - Seminoma

Seminoma - Germ cell tumor of testicle/ rarely mediastinum or other extra-gonadal locations.

Malignant neoplasm;

One of most treatable & curable cancers;

Survival rate >95% if discovered in early stages.

Usually unaffected fertility & other sexual functions remains intact.

Originates in germinal epithelium of seminiferous tubules

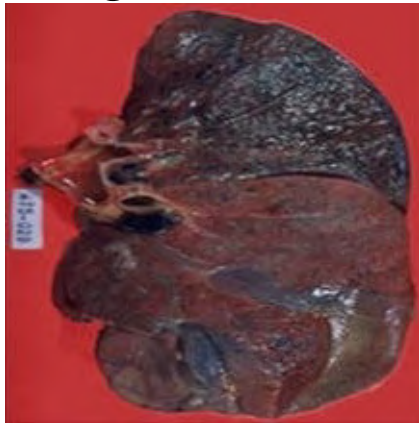
Histology:

- Typically prominent lymphocytic infiltrate in the fibrous stroma separating the clusters of tumor cells.

Treatment:

- Requires removal of one testicle.

214. Identify the condition shown in the image.



a) Lobar Pneumonia

b) Bronchopneumonia

c) Acute glomerulonephritis

d) Congested kidney

Correct Answer - A

Answer: A- Lobar Pneumonia

Image depicts the **red hepatization of lungs**

Red hepatization is seen in conditions like **lobar pneumonia**.

Lobar Pneumonia:

- Pneumococcal pneumonia - Most common cause of lobar pneumonia
- Progresses from a red hepatization phase to a gray hepatization phase

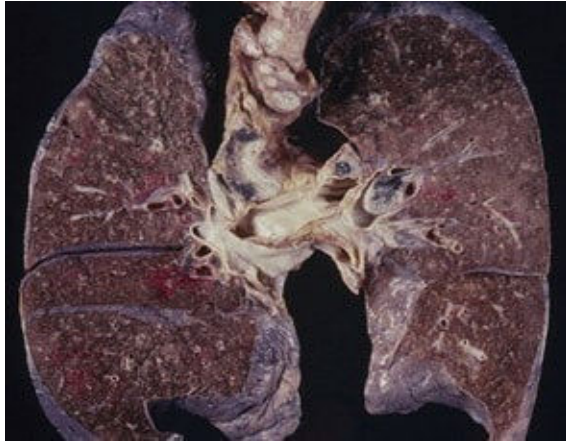Red hepatization:

- Characterized by consolidation of airspaces of lungs.
- C/S reveals lungs appear brown-red, firm, & airless. resembling liver.

Histological:

- Congested alveolar capillaries & alveolar spaces are filled with erythrocytes, neutrophils, and fibrin.
- Red cells disintegrate, with persistence of the neutrophils and fibrin.

215. Identify the condition represented in below image



a) Miliary tuberculosis

b) Bronchiectasis

c) COPD

d) Lung cancer

Correct Answer - A

Answer: A- Miliary tb

Miliary tuberculosis (TB) is widespread dissemination of *Mycobacterium tuberculosis*

Result of hematogenous spread.

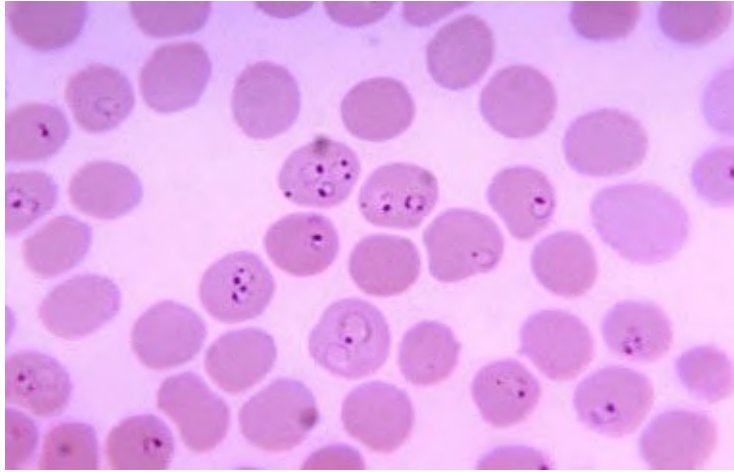
Distinctive pattern seen on a chest radiograph

Tiny sized lesions (1–5 mm), seen as tiny spots distributed throughout lung fields appearing similar to millet seeds

Hence, the term "miliary" tuberculosis.

Miliary TB may also infect liver & spleen.

216. Identify the organism related to blood smear image -



a) *P. falciparum*

b) *S. Typhi*

c) *Treponema pallidum*

d) *Toxoplasma gondii*

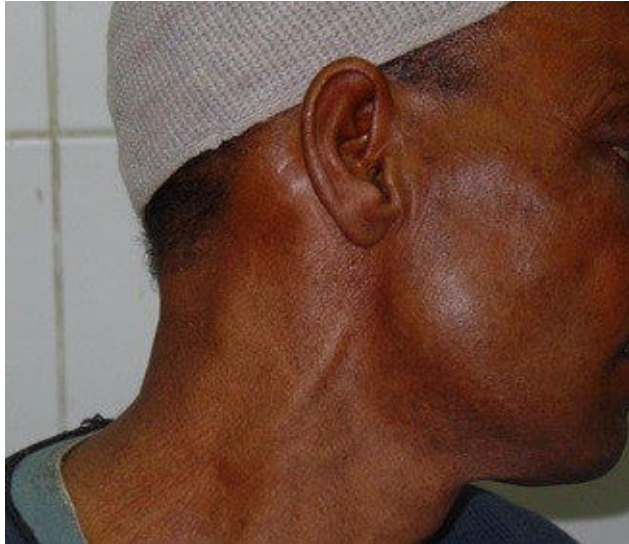Correct Answer - A

Answer: A.--> *P. falciparum*

- Malaria parasite can be seen in the blood smear of patients affected by the disease at specific stages in the disease.
- *Plasmodium falciparum*—ring-shaped trophozoite. The red blood cell containing four ring-shaped trophozoites.
- Note the very high percentage of red cells containing ring forms.
- This high-level parasitemia is more often seen in *Plasmodium falciparum* infection than in infection by the other plasmodia.
- The thick smears allow detection whereas the thin smears allow identification of the species. This thin smear shows multiple malaria

trophozoites inside red blood cells (Early ring form). However, trophozoites can also be seen outside red blood cells.

217. Which is thickened nerve shown here:



a) Facial Nerve

b) Greater auricular nerve

c) Vagus Nerve

d) Glossopharyngeal Nerve

Correct Answer - B

Answer- B. Greater auricular nerve

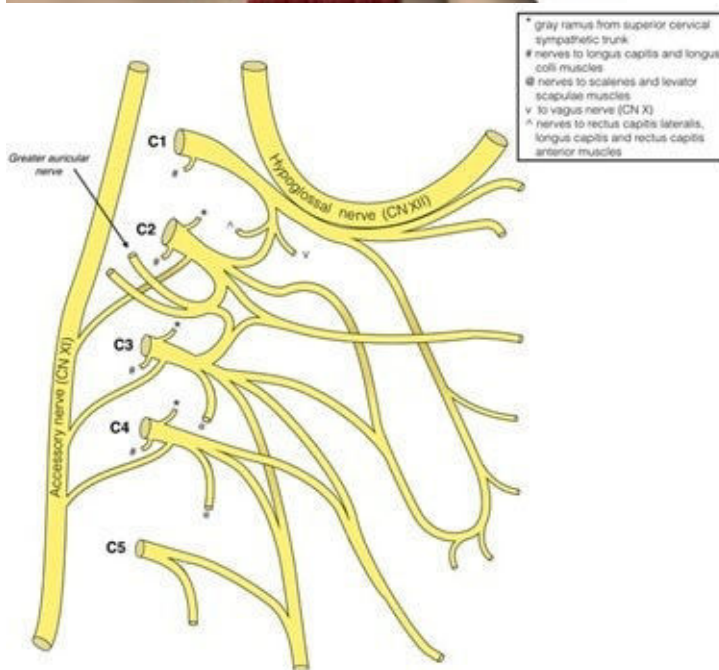
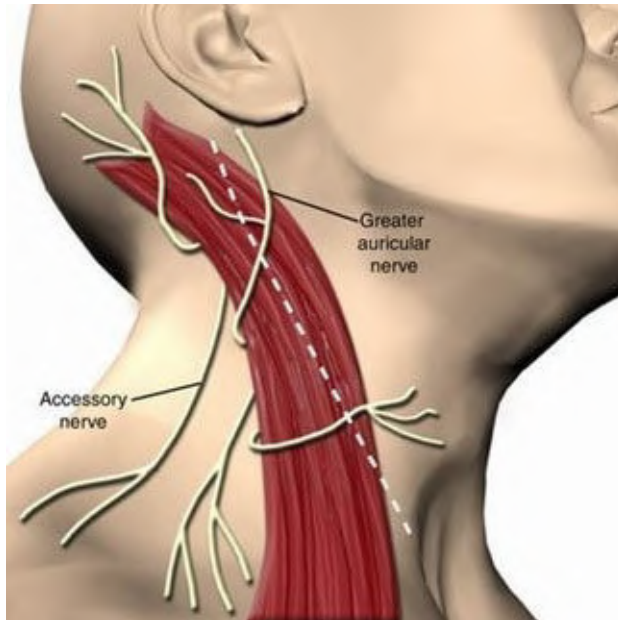
The greater auricular nerve is a cutaneous branch of the cervical plexus that innervates the skin of the auricle as well as skin over the parotid gland and mastoid process. The greater auricular nerve also supplies branches that innervate the deep layer of the parotid fascia.

Origin

- The greater auricular nerve arises from the ventral rami of C2 and C3 spinal nerves , although it receives considerably more fibres from C2.

Course

- The greater auricular nerve emerges along the posterior aspect of the sternocleidomastoid muscle at the punctum nervosum (Erb point) and ascends vertically across the oblique sternocleidomastoid muscle. When the greater auricular nerve approaches the inferior pole of the parotid gland it divides into anterior and posterior terminal branches.



218. Which type of retractor is shown in the image



a) Morris retractor

b) Czerny retractor

c) Richardson retractor

d) Lower lid retractor

Correct Answer - A

Answer: A. Morris retractor

Morris retractor-

- This is a big retractor which is useful for giving maximum exposure in large incisions such as those used in the abdomen.
- It can be used to improve visibility on one side of an incision (by putting firmly in that direction); so is valuable during the initial phase of a laparotomy.
- Sir Henry Morris (1844-1926) was a surgeon at the Middlesex Hospital. London, UK.

219. Which of the following statement is true about suture material in the image:



- a) Made of rabbit submucosa
- b) Made of cat submucosa
- c) Not degraded
- d) Degraded by enzymatic degradation

Correct Answer - D

Answer: D. Degraded by enzymatic degradation

Catgut-

Types- plain

Raw material- Collagen derived from healthy sheep or cattle

Tensile strength retention in vivo- Lost within 7-10 days. Marked patient variability. Unpredictable and not recommended.

Absorption rate- Phagocytosis and enzymatic degradation within 7-10 days

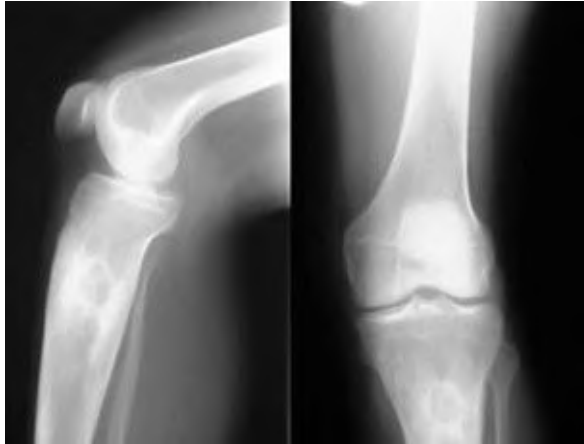Tissue reaction- high

Contraindications- Not for use in tissues that heal slowly and require prolonged support. Synthetic absorbable is superior.

Uses- Ligate superficial vessels, suture subcutaneous tissues.

Stomas and other tissues that heal rapidly.

220. A Patient has history of RTA 2 years back, at the same sight he developed pain and swelling. Xray shows the following features . What will be the diagnosis?



a) Osteogenic sarcoma

b) Ewing's sarcoma

c) Chronic osteomyelitis

d) Multiple myeloma

Correct Answer - C

Ans. C. Chronic osteomyelitis

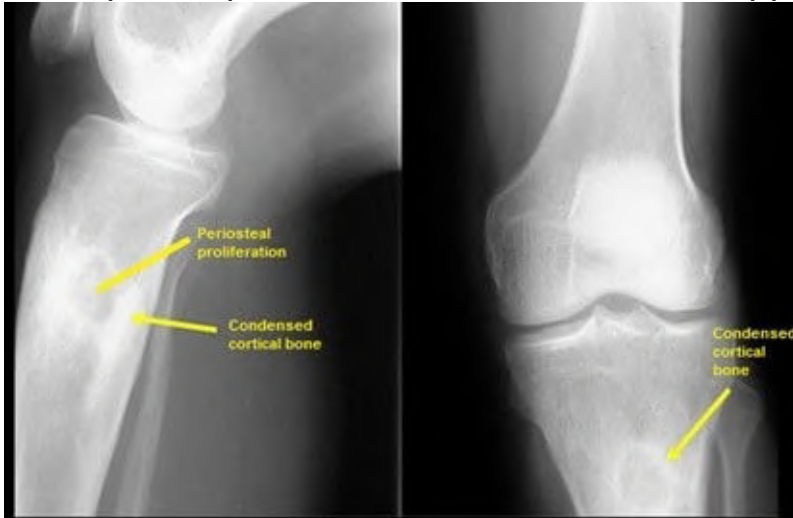
Garré sclerosing osteomyelitis, or chronic nonsuppurative sclerosing osteomyelitis, is a form of chronic osteomyelitis.

Mild inflammation and infection lead to subperiosteal bone deposition.

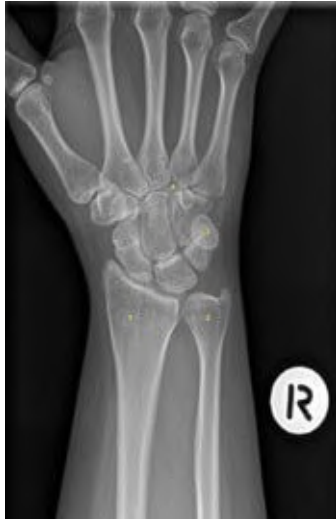The disease is frequently asymptomatic.

The characteristic radiographic appearance is an area of periosteal

proliferation surrounded by successive layers of condensed cortical bone (*arrows*), described as an onion skin appearance.



221. Identify the bone numbered in the X-ray below that most commonly fracture when a person falls on outstretched hands?



a) 1

b) 2

c) 3

d) 4

Correct Answer - A

Ans. A. 1

A distal radius fracture, also known as a wrist fracture, is a break of the part of the radius bone which is close to the wrist.

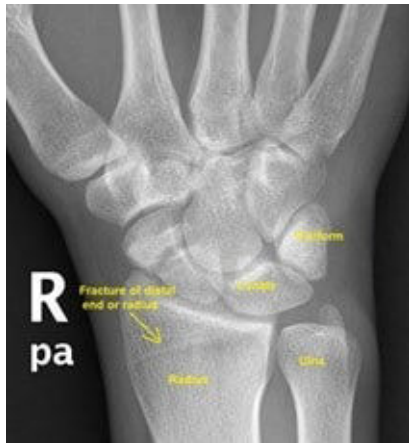Symptoms include pain, bruising, and swelling of rapid onset

The wrist may be deformed.

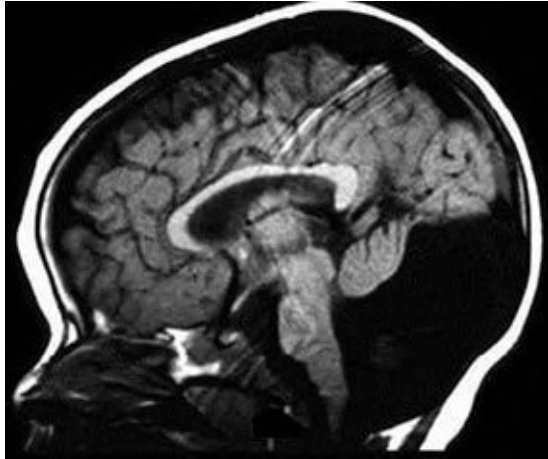
In younger people, these fractures typically occur during sports or a motor vehicle collision. In older people, the most common cause is

falling on an outstretched hand.

Specific types include Colles, Smith, Barton, and Hutchinson fractures



222. Identify the condition shown in the CT Scan image below.

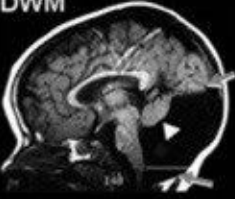
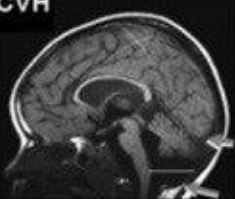
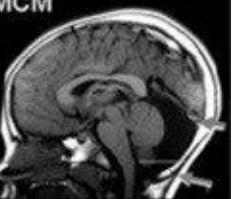


- a) Dandy walker malformation
- b) Cerebellar vermis hypoplasia
- c) Mega cisterna magna
- d) None

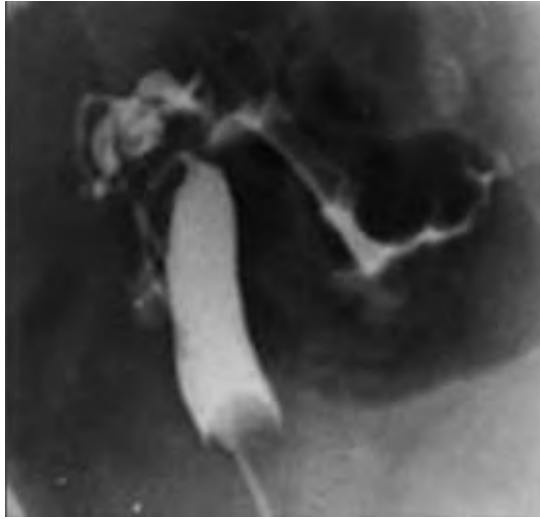
Correct Answer - A

Ans. A.Dandy walker malformation

DWM spectrum phenotypes

DWM	CVH	MCM
		
Dandy Walker Malformation: -small vermis -rotation of vermis -big posterior fossa	Cerebellar Vermis Hypoplasia: -small vermis -NO rotation -normal posterior fossa	Mega Cisterna Magna: -normal vermis (CVH?) -NO rotation -big posterior fossa

223. Identify the X ray HSG Shown below :



a) Septate uterus

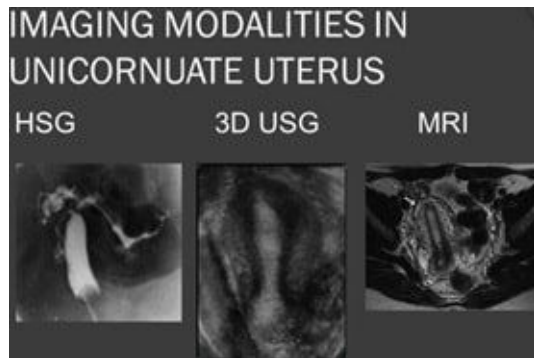b) Uterus didelphys

c) Unicornuate uterus

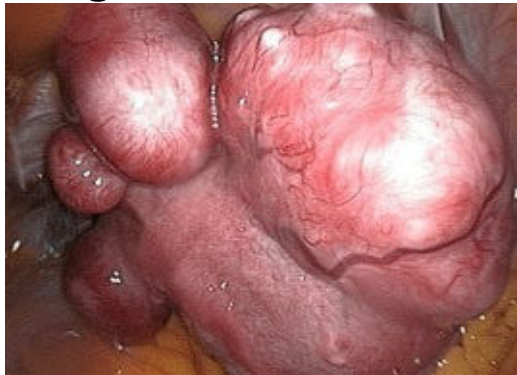d) Bicornuate uterus

Correct Answer - C

Ans. C. Unicornuate uterus



224. In a woman complaining of AUB following image was seen in endoscopic examination of uterus. What will be the diagnosis?



a) Leiomyoma

b) Adenomyosis

c) Ovarian neoplasm

d) Carcinoma of uterus

Correct Answer - A

Ans. A . Leiomyoma

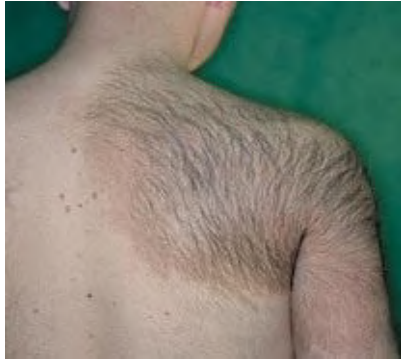Leiomyoma is the most common pelvic tumor in women

Benign, originate from myometrial smooth muscles

Symptoms include:

- AUB
- Pelvic pain and pressure
- Infertility or adverse pregnancy outcome

225. Identify the following lesion.



a) Becker nevus

b) Hypopigmented macule

c) Spitz nevus

d) Epidermal nevus

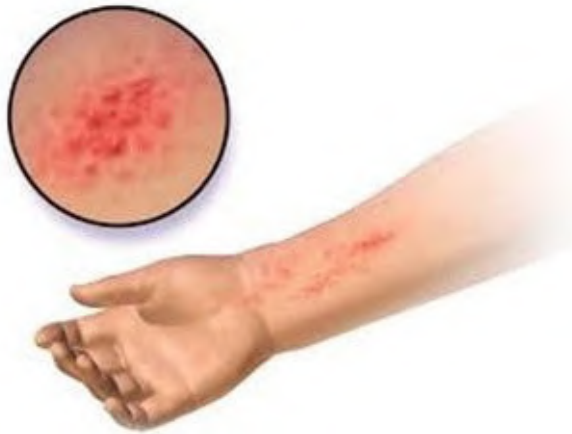Correct Answer - A

Ans. A.

Becker Nevus:

- Usually starts in adolescence as an irregular smooth hyperpigmented macule.
- Usually involves the shoulder, anterior chest and scapular region.
- Slowly grows in size of a palm while acquiring thick dark hair.
- Often lesion resembling acne vulgaris in different stages may appear on the surface.
- No treatment is required.

226. A child has a rash as shown in the picture .His family history is positive for asthma . What could be the most probable diagnosis ?



a) Seborrheic dermatitis

b) Atopic dermatitis

c) Allergic contact dermatitis

d) Erysipelas

Correct Answer - C

Ans. C. Allergic contact dermatitis

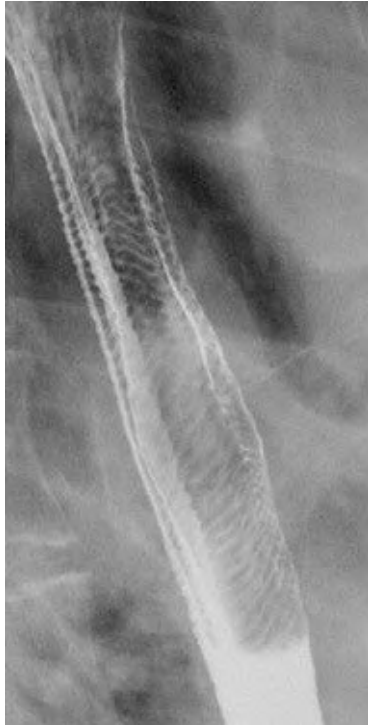ACD is a form of contact dermatitis that manifests as an allergic response caused by contact with a substance .Its a hypersensitive reaction characterised by the presence of rash or a skin lesion in the form of papules , blisters or vesicles etc . The differential features are

It is confined to the area where the trigger touched the zone,
It occurs after a day or two of the exposure and

The svmntoms reannear when in contact with the allergen .

The symptoms reappear when in contact with the allergen.

227. Spot radiograph from a double contrast esophagram. Image represents:



a) Esophageal atresia

b) Esophageal stenosis

c) Feline oesophagus

d) Tracheoesophageal fistula

Correct Answer - C

Answer- C. Feline oesophagus

- In the given image, there are numerous 1-2 mm radiolucent folds across the esophagus. The folds are angled concerning to the center of the esophagus in a "herringbone" pattern.
- The folds occur transiently.
- The feline esophagus also is known as an oesophageal shiver, refers to the transient

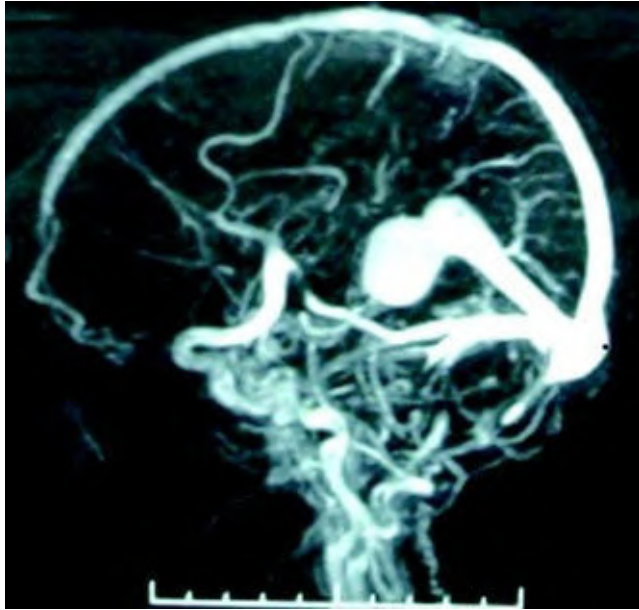
transverse bands seen in the mid and lower esophagus on a double-contrast barium swallow.

- These fine mucosal folds are a transient finding produced by contraction of the muscularis mucosa. A similar appearance may be seen in cats. It is usually a normal variant but may be associated with GERD.
- These fine folds are probably of no significance and relate to the technique as they are most often seen when the esophagus is only partially distended.

Radiographic features

- The folds are 1-2 mm thick and run horizontally around the entire circumference of the oesophageal lumen. The findings are transient, seen following reflux and not during swallowing. The appearance is confined to the distal two-thirds of the thoracic esophagus.

228. MRI of skull represents:



- a) Vein of Galen
- b) Dandy walker Syndrome
- c) Pneumocephalus
- d) Crouzon syndrome

Correct Answer - A

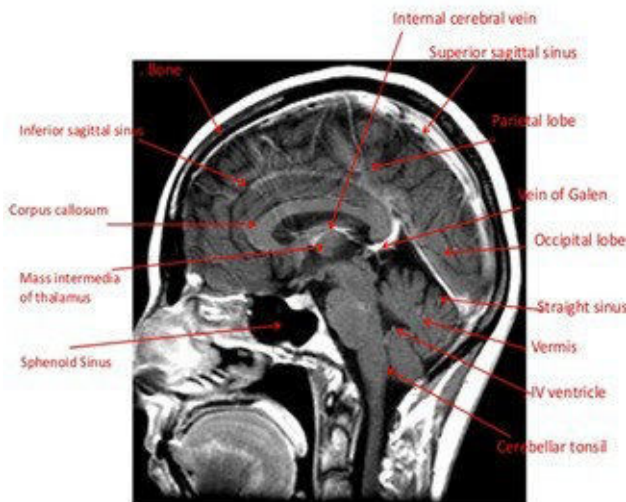
Answer A. Vein of Galen

The vein of Galen is located under the cerebral hemispheres and drains the anterior and central regions of the brain into the sinuses of the posterior cerebral fossa.

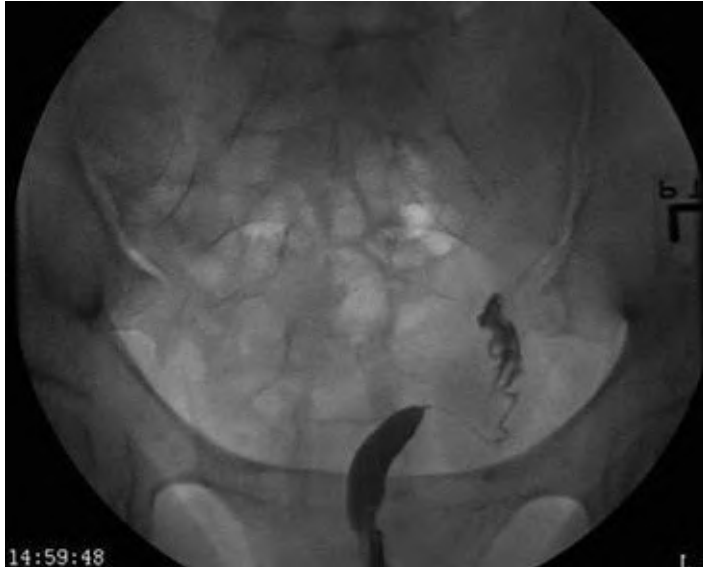The vein of Galen, also known as the great cerebral vein or **great vein of Galen**, is a short trunk formed by the union of the two internal cerebral veins and basal veins of Rosenthal. It lies in the quadrigeminal cistern. It curves backward and upward around the posterior border of the splenium of the corpus callosum to drain into

the confluence of the inferior sagittal sinus and the anterior extremity of the straight sinus.

Aneurysmal malformations of Vein of Galen Malformations (VGAM) typically results in high output congestive heart failure or may represent developmental delay, hydrocephalus and seizures. VGAM results from aneurysmal malformation with arteriovenous shunting of blood.



229. What is a diagnosis based on a given image:



a) Uterus didelphys

b) Bicornuate Uterus

c) Unicornuate Uterus

d) Septate uterus

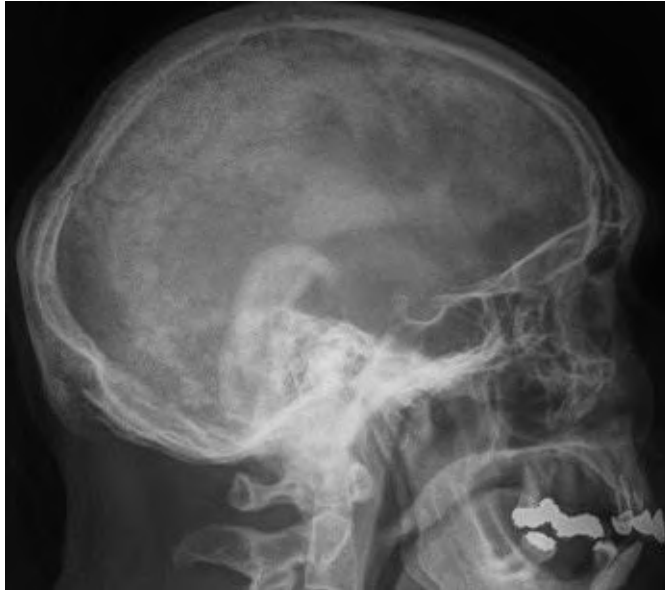Correct Answer - C

Answer-C. Unicornuate Uterus

- **Above image is unicornuate uterus as seen on a hysterosalpingogram represents:**
- This results from failure of normal development of one Müllerian duct and is associated with increased spontaneous abortion and obstetric complications, and renal abnormalities.
- On T2-weighted MR images, the unicornuate uterus demonstrates a curved, elongated uterus with tapering of the fundal segment off

midline (the 'banana-like' configuration) best seen on the axial oblique (long axis) images.

230. X-ray of skull showing which lesions in the brain:



a) Paget's disease

b) Multiple myeloma

c) Osteosarcoma

d) Osteomyelitis

Correct Answer - A

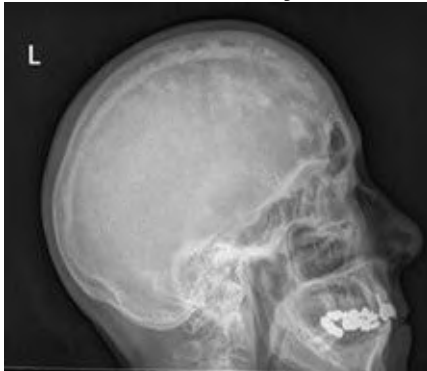Answer- A. Paget's disease

Paget disease of the bone is a common, chronic bone disorder characterized by excessive abnormal bone remodeling. It frequently affects the pelvis, spine, skull and proximal long bones and has characteristic radiographic features.

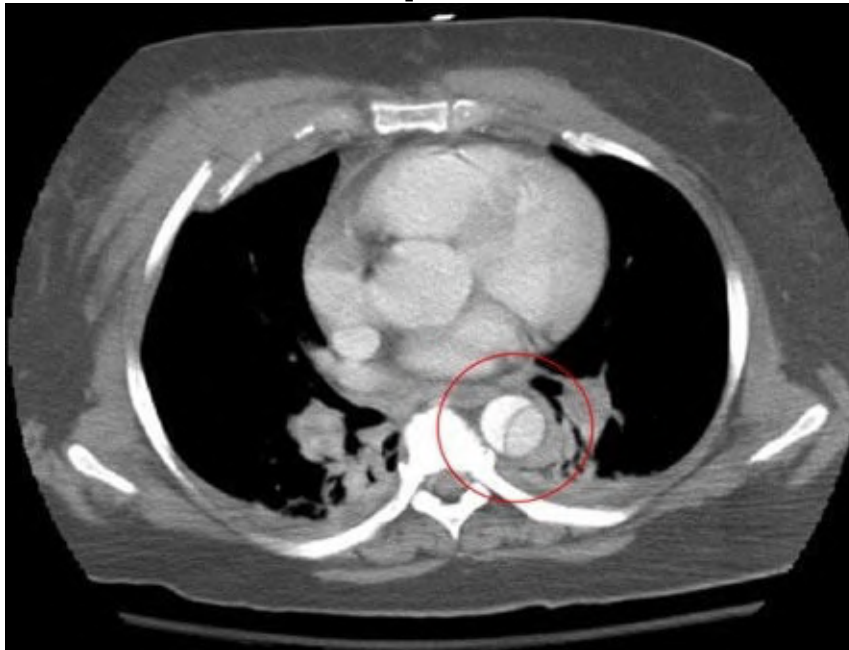
Radiographic features

- The condition is found most commonly in the sacrum and lumbar spine, followed by skull, pelvis, and femur.

- In the skull, the disease begins as a destructive process affecting the outer table and sparing the inner table.
- The full picture of osteoporosis circumscripta is rarely seen. In the reparative stage, sclerosis of the inner table is pronounced, and later the diploic spaces and the outer table become thickened.
- A classical, widespread 'cottonwool' effect results.
- The cranial cavity is not encroached upon.



231. CT of Thorax represents:



- a) Ascending Aortic dissection
- b) Descending Aortic dissection
- c) Aortic aneurysm
- d) Cystic fibrosis

Correct Answer - B

Answer B. Descending Aortic dissection

Aortic dissection is a devastating disease that occurs as a result of the degeneration of the thoracic aorta.

Middle-aged men are the most often affected with only 5% of dissections occurring in the under 40 age group.

The classical presentation is the sudden onset of a razor-sharp pain between shoulder blades.

There are two major types of classification, the De Bakey and the

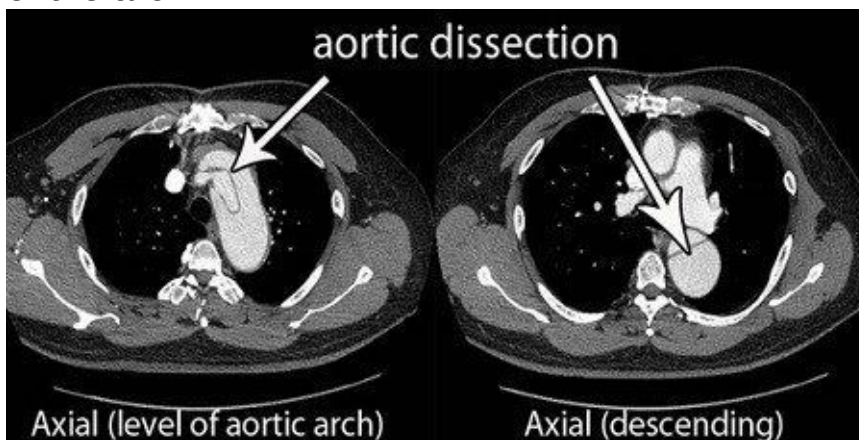
Stanford.

The Stanford classification is simpler with two types of dissection described, Type A and Type B. Type A is equivalent to a De Bakey Type I or Type II dissection, involving the ascending arch, whereas Type B just involves the descending aorta. Type A is generally treated with urgent surgery with Type B generally being treated conservatively.

Sign on chest radiograph-

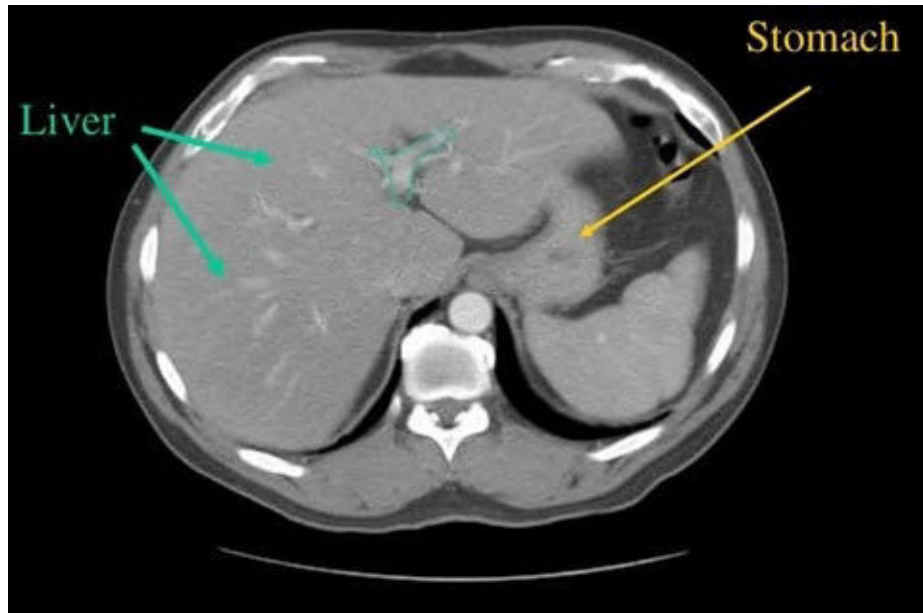
The most common abnormality is the widening of the mediastinum which is often associated with an indistinct outline of the aorta or an irregular wavy contour.

More characteristic but a less frequent radiological finding is localized dilatation of the aortic knuckle and upper descending aorta, giving rise to a prominent hump sign which will indicate aneurysmal dilatation or unfolding of the arch.



The CT scan will show the true and false lumens associated with dissection.

232. CT scan of abdomen showing an area that branching into the liver. Identify the structure?



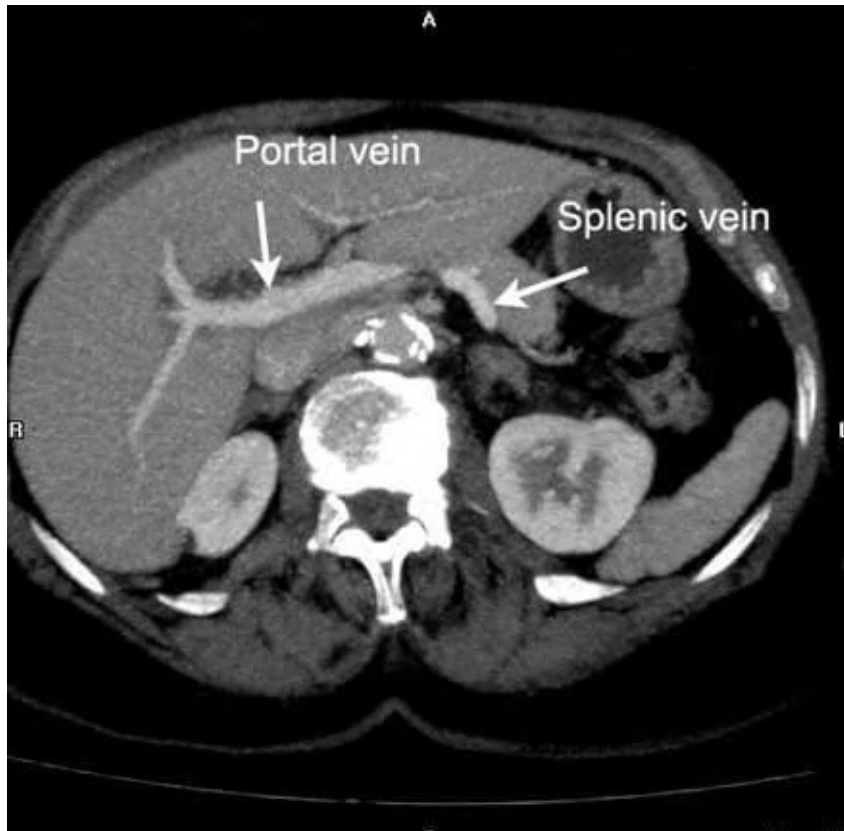
a) SVC

b) IVC

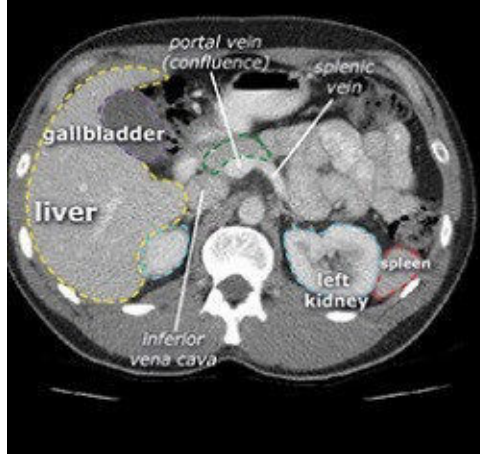
c) Portal vein

d) Splenic vein

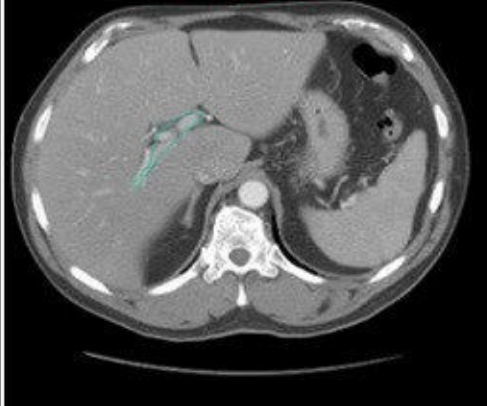
Correct Answer - C
Ans: C. Portal vein

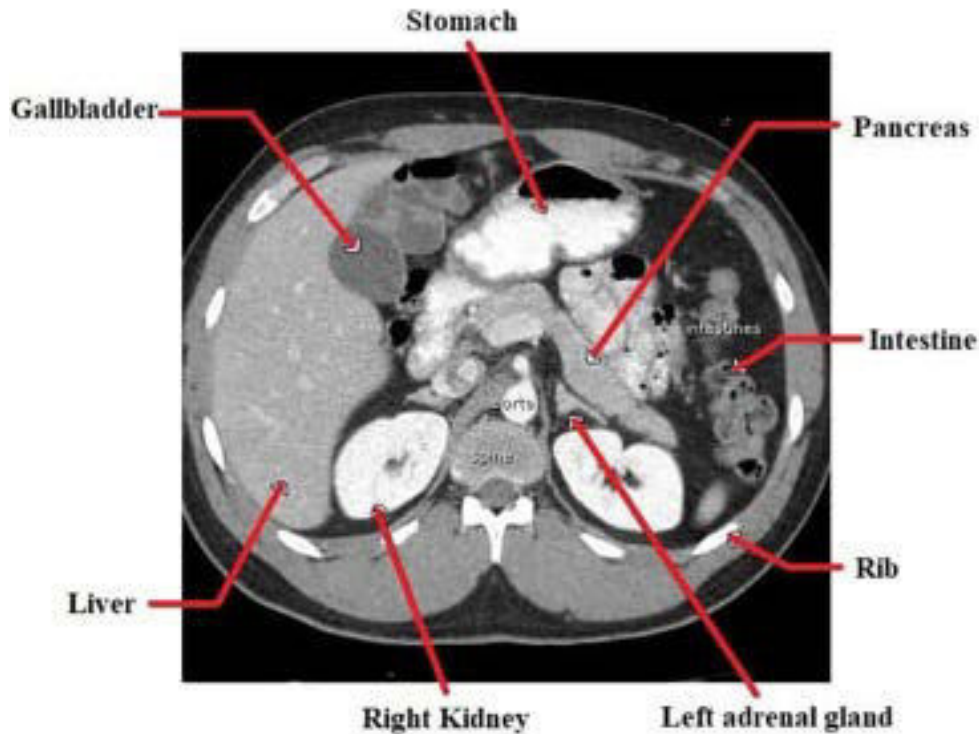


Normal abdominal CT



More portal vein branching into the liver lobes



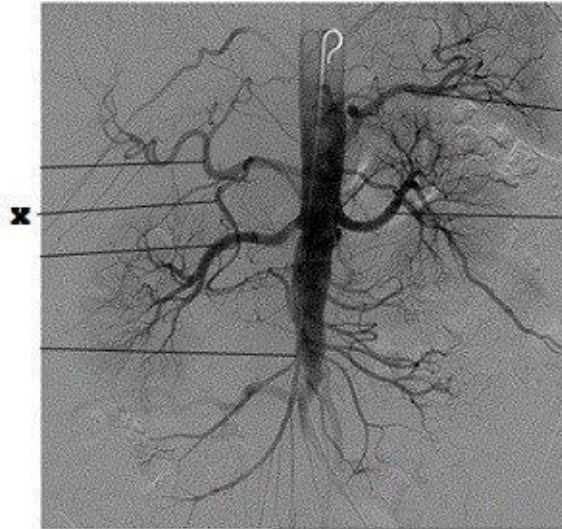


The **portal vein** or **hepatic portal vein** is a blood vessel that carries blood from the gastrointestinal tract, gall bladder, pancreas, and spleen to the liver.

The liver is further subdivided into Couinaud segments based on the vascular supply.

The caudate lobe or segment I have autonomous blood supply from both left and right branches of the portal vein and hepatic artery along with independent venous drainage directly into the IVC.

233. Identify artery 'X' in the given angiography anatomy image:



a) Superior mesenteric artery

b) Subclavian artery

c) Celiac artery

d) Brachiocephalic artery

Correct Answer - A

Answer – A. Superior mesenteric artery

The superior mesenteric artery (SMA) is a major artery of the abdomen. It arises from the abdominal aorta, and supplies arterial blood to the organs of the midgut – which spans from the major duodenal papilla (of the duodenum) to the proximal 2/3 of the transverse colon.

Anatomical Position

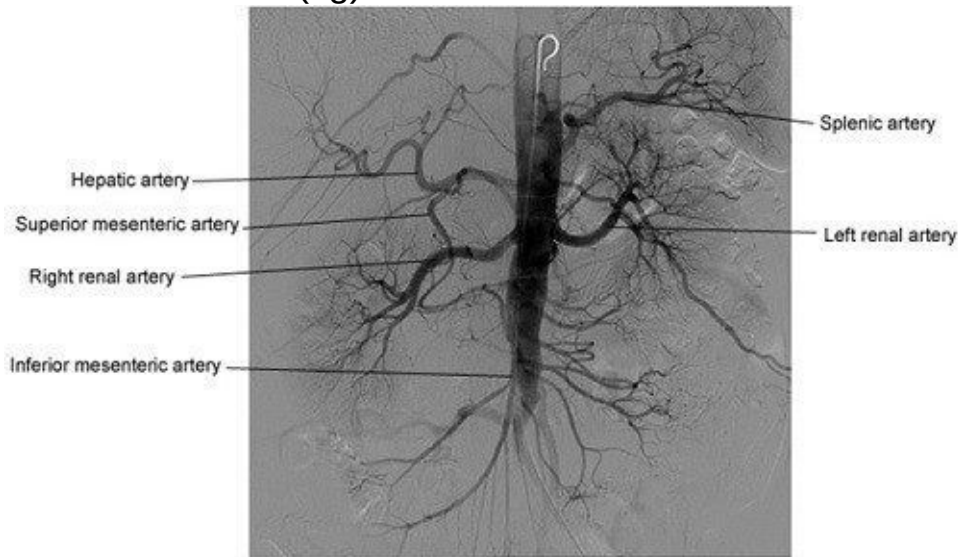
The superior mesenteric artery is the second of the three major anterior branches of the abdominal aorta (the other two are the coeliac trunk and inferior mesenteric artery). It arises anteriorly from the abdominal aorta at the level of the L1 vertebrae, immediately inferior to the origin of the coeliac trunk.

After arising from the abdominal aorta, the superior mesenteric artery descends down the posterior aspect of the abdomen. At this point, it has several important anatomical relations:

- **Anterior to the SMA** – pyloric part of the stomach, splenic vein and neck of the pancreas.
- **Posterior to the SMA** – left renal vein, uncinate process of the pancreas and inferior part of the duodenum.
- The uncinate process is the only part of the pancreas that hooks around the back of the SMA.

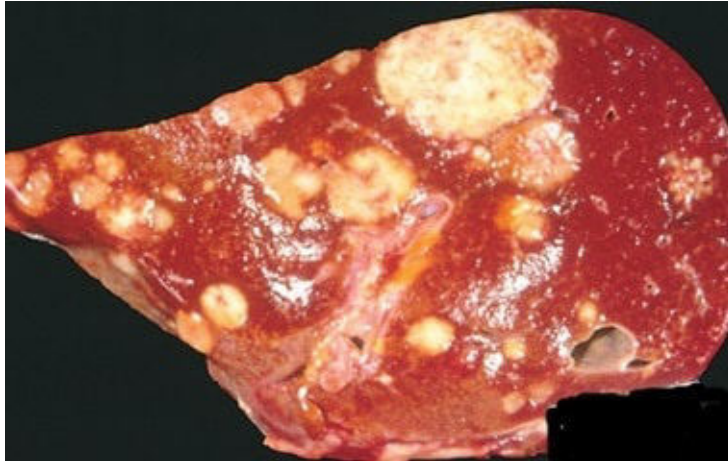Major Branches

- The superior mesenteric artery then gives rise to various branches that supply the small intestines, cecum, ascending and part of the transverse colon (fig).



The superior mesenteric artery and its branches.

234. A woman shows symptoms of massive pulmonary thromboembolism. The gross appearance of liver autopsy is shown. Which of the following statement best characterizes the patient's condition?



a) Metastasis from PE

b) Angiosarcoma

c) Colonic adenocarcinoma with metastasis

d) Locally invaded hepatocellular carcinoma

Correct Answer - C

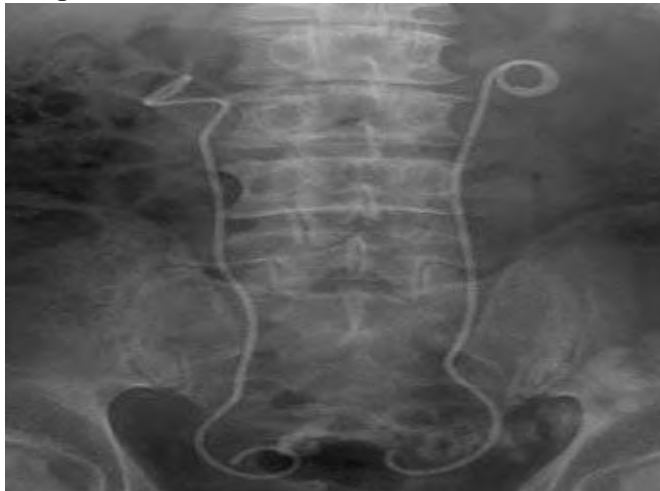Answer: C. Colonic adenocarcinoma with metastasis

The figure shows appearance of metastatic lesions from a malignant neoplasm with multiple tumor masses

The liver is the most common site of metastases for tumor sites that drain initially via the portal circulation. Metastatic liver disease is found in 10% to 25% of patients having surgery for primary colorectal cancer

Surgical resection is the most effective therapy for metastatic colorectal cancer isolated to the liver.

235. What is the structure seen in the given X-ray below



a) Stent

b) Surgical clips

c) Foley catheter

d) Intravesical wire

Correct Answer - A

Ans. A. Stent

Plain abdominal X-ray showing a stent in the right and left ureter.

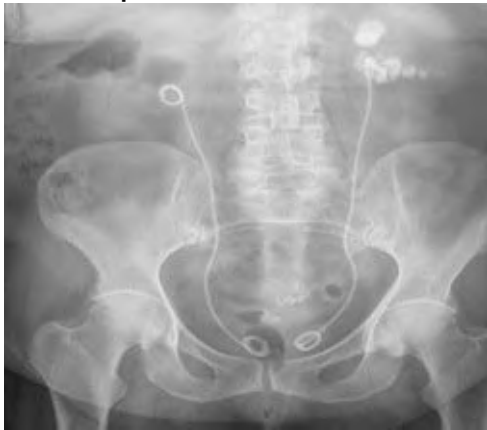Ureteric stents, also known as **double J stents** or **retrograde ureteric stents**, is a urological catheter that has two "J-shaped" (curled) ends, where one is anchored in the renal pelvis and the other inside the bladder.

- Ureteral stents are implants used to provide drainage of the upper urinary tract when obstruction of the ureter is present or anticipated. This obstruction may be due to internal or external issues, such as edema after manipulation of the ureter, ureteral stricture, passage of

stone fragments or external compression of the ureter. Stents are also frequently used in reconstructive surgery.

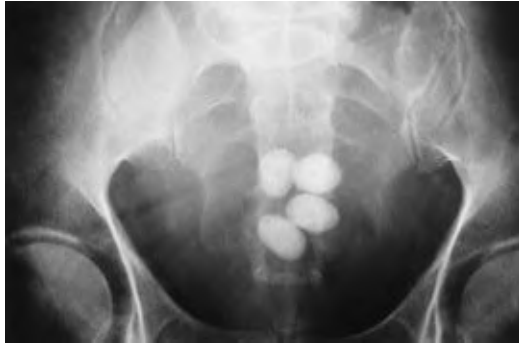Stent-related complications

Development of UTIs or formation of encrustations, complicating subsequent stent removal.



bilateral ureteric stents

236. What is the diagnosis based on the following X-ray?



a) Uterine Fibroid

b) Bladder Carcinoma

c) Bladder stone

d) Renal Tuberculosis

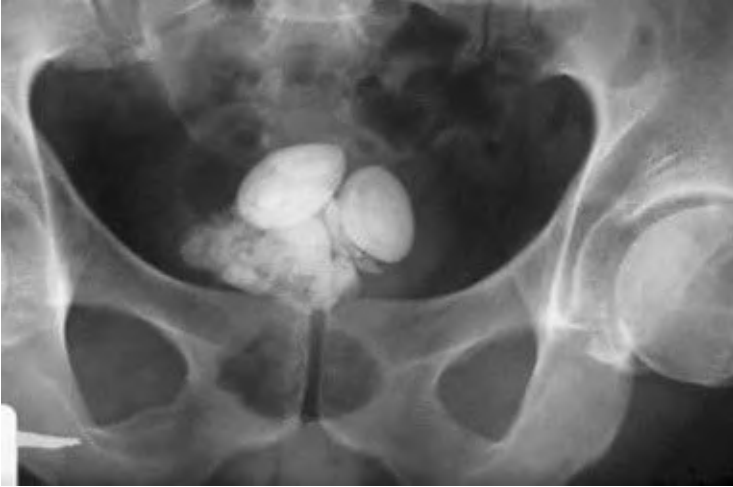Correct Answer - C

Ans. C. Bladder stone

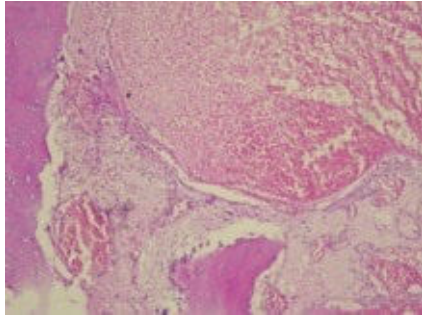
- Multiple bladder calculi. Four oval radiopaque bladder stones are visible centrally in the pelvis. Most bladder calculi are round or oval, but they may also be amorphous, laminated, or even speculated.
- Calculi may form as a result of infection (especially with proteus in an abnormally functioning bladder) when the calculi are magnesium ammonium phosphate and apatite.
- Calculi are often asymptomatic but may present with haematuria, suprapubic pain, disruption of the urine stream or recurrent infection.
- They may appear as radiopaque spiculated (jackstone), laminated or amorphous lesions.
- As with upper tract calculi, on contrast investigations, they are usually seen as filling defects, as they are mostly less radiopaque

than contrast.

- Ultrasound reliably demonstrates them as highly echogenic mobile foci, especially when the bladder is full.



237. A red soft to firm swelling on sternum that on biopsy shows following histology. What is the diagnosis?



a) Hemangioma

b) Osteochondroma

c) Osteoid osteoma

d) Paget disease

Correct Answer - A

Ans. A. Hemangioma

Clinical presentation

- These tumours are slow growing and are generally asymptomatic unless they exert mass effect on sensitive structures. Occasionally they may present as a swelling or a palpable mass, especially in the skull. When large and strategically located they may present with a pathological fracture.
- If they are high-flow lesions, shunt-related symptoms may also be present.

Pathology

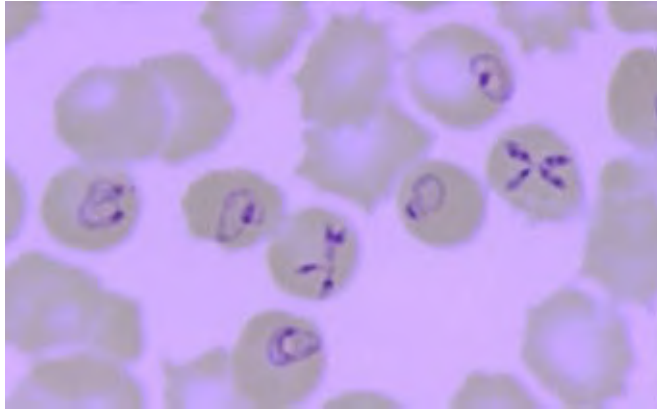
- Primary intraosseous haemangiomas are slow growing vascular neoplasms, usually located in the medullary cavity. They are

classified as benign, but rarely may be locally aggressive.

Histology

- Histologically, intraosseous haemangiomas demonstrate hamartomatous vascular tissue within endothelium, but may also contain fat, smooth muscle, fibrous tissue, and thrombi.

238. Which of the following is carrying agent for the disease with given characteristic on polarized microscopy?



a) Anopheles

b) Ixodes scapularis ticks

c) Louse

d) Rat flea

Correct Answer - B

Answer: B. Ixodes scapularis ticks

- Babesiosis infects the RBCs and resides inside the RBCs (intraerythrocytic).
- Intraerythrocytic infection of Babesiosis is characterized by the maltese cross.
- The Maltese cross is a characteristic arrangement of parasites within the erythrocytes → Parasites within erythrocytes are arranged such that pointed ends of four parasites come in contact thereby giving a tetrad configuration resembling a maltese cross.
- Tetrad forms or 'Maltese cross' appearance is considered

pathognomic of Babesiosis.

- Babesiosis can easily be confused with P. falciparum malaria. Following two features distinguish Babesiosis from malaria
 - Presence of maltese cross in Babesiosis (absent in malaria)
 - Absence of pigment Hemozoin in Babesiosis (present in malaria)
- Note** - Maltese cross is also seen in cryptococcus and aspergillus.

239. Chordoma arises from:

a) Pharyngeal bursa

b) Notochord

c) Rathke's pouch

d) Luschka's bursa

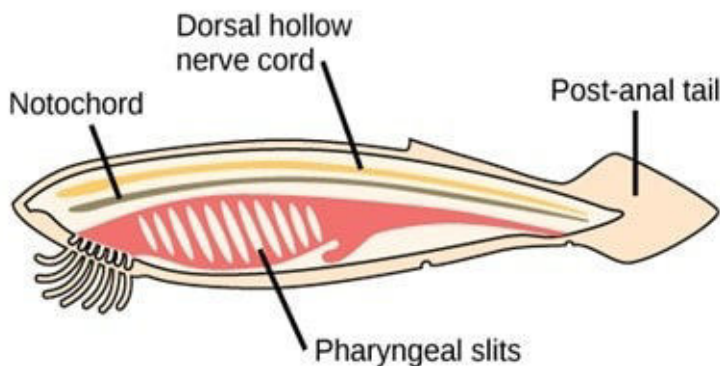
Correct Answer - B

Answer: - B. Notochord

Chordoma is a rare slow-growing neoplasm thought to arise from cellular remnants of the notochord.

Chordomas can arise from bone in the skull base and anywhere along the spine. The two most common locations are cranially at the clivus and in the sacrum at the bottom of the spine.

There are three histological variants of chordoma: classical (or "conventional"), chondroid and dedifferentiated.



240. What is the effect of Progesterone only pills?

- a) Completely suppresses ovulation
- b) Thin lining of uterus
- c) Thick cervical mucus
- d) All of the above

Correct Answer - D

Answer: D. All of the above

Progestogen-only pills / Progestin-only Pills (POP) / Morning after pills -

Contraceptive pills

Contain only synthetic progestins & doesn't contain estrogen.

Mechanism:

- Mucus thickening in the neck of the womb:
- Penetration of sperm to reach egg and womb becomes difficult.
- Prevents ovulation:
- The lining of the uterus becomes thin
- Fertilized egg implantation is prevented

Advantages:

- Doesn't interfere with breastfeeding
- Also helps in premenstrual symptoms and painful periods

241. Which metal results in “Saturnine gout” formation?

a) Cadmium

b) Lead

c) Beryllium

d) Mercury

Correct Answer - B

Answer: B. Lead

One manifestation of chronic lead toxicity is the rheumatologic entity known as saturnine gout.

Illicitly distilled beverages may inadvertently contain harmful toxins, like metallic lead.

Lead has been known to play a role in purine metabolism & renal insufficiency

242. Which drug decreases the bone resorption in osteoporosis?

a) Teriparatide

b) Risedronate

c) Cortisone

d) Cimetidine

Correct Answer - B

Answer: B - Risedronate

Risedronate bisphosphonates inhibits bone resorption by actions on osteoclast precursors in osteoporosis patients

Risedronate:

- Aminobisphosphonate

Indications:

- Prevention & treatment of osteoporosis

Mechanism of action:

- Inhibits bone resorption by action on osteoclasts
- Reduce bone remodelling
- More potent in blocking the bone dissolution process.
- Teriparatide, an PTH analog, recombinant human PTH is also used, yet in severe cases of osteoporosis, improving the skeletal microarchitecture

243. Phenylketonuria is due to deficiency of:

- a) Phenylalanine
- b) Phenylalanine hydroxylase (PAH)
- c) Phenylene
- d) All of these

Correct Answer - B

Answer B. Phenylalanine hydroxylase (PAH)

A birth defect that causes an amino acid called phenylalanine to build up in the body.

PKU is an [autosomal](#) recessive metabolic genetic disorder.

PKU is characterized by homozygous or compound heterozygous mutations in the gene for the hepatic enzyme **phenylalanine hydroxylase (PAH)**, rendering it nonfunctional.

This enzyme is necessary to metabolize the amino acid phenylalanine (Phe) to the amino acid tyrosine (Tyr). When PAH activity is reduced, phenylalanine accumulates and is converted into phenylpyruvate (also known as phenylketone), which can be detected in the urine.

The PAH gene is located on chromosome 12 in the bands 12q22-q24.1. More than 400 disease-causing mutations have been found in the PAH gene.

244. WHICH IS NOT CORRECT:

a) MRI needed to access haemorrhage

b) GCS assessment helps in prognosis

c) Haematoma must be operated

d) all of the above

Correct Answer - C

Answer- C. Haematoma must be operated

Treatment of hematoma depends on the location, symptoms, and the clinical situation. Some may require no treatment at all while others may be deemed a medical emergency.

Simple therapies at home may be utilized in treating superficial (under the skin) hematomas. Most injuries and bruises can be treated with resting, icing, compression, and elevating the area. This is remembered by the acronym **RICE**.

These measures usually help to reduce inflammation and diminish its symptoms.

- **Rest**
- **Ice** (Apply the ice or cold pack for 20 minutes at a time, 4 to 8 times a day.)
- **Compress** (Compression can be achieved by using elastic bandages.)
- **Elevate** (Elevation of the injured area above the level of the heart is recommended.)

Medical treatment for a hematoma

- For certain small and symptom-free hematomas no medical treatment may be necessary. On the other hand, symptomatic hematomas or those located in certain locations sometimes require medical or surgical treatment.

- Even though no specific medication is available for the treatment of hematomas, management of any related symptoms can be achieved by medications. For example, pain from a hematoma can be treated with pain medications such as acetaminophen ([Tylenol](#)).
- Surgical drainage is a common method of treatment for certain hematomas.

245. Maastricht classification of donation after cardiac death. What category is stage 3 ?

- a) Awaiting cardiac arrest
- b) Brought in dead
- c) Unsuccessful resuscitation
- d) Cardiac arrest after brain-stem death

Correct Answer - A

Answer: A>Awaiting cardiac arrest

The first level of definition is simple and based on whether the situation is uncontrolled (categories I and II) or controlled (categories III, IV, and V).

Category I, the patient is declared "dead on arrival" and,

Category II, there is an "unsuccessful resuscitation" whether it occurred out or in the hospital for both situations.

Category III is the most usual situation in which the treating physician and family are "awaiting cardiac arrest" to declare the death of the patient.

Category IV is always characterized by "cardiac arrest during brain death." The special situation of the Belgian law allowing the euthanasia is elaborated

Category V "euthanasia," and includes patients who grant access to medically assisted circulatory death. Organ donation after euthanasia is allowed under the scope of donation after circulatory

246. What is the cause of myocardial shock other than MI ?

a) acute mitral regurgitation

b) ventricular septal rupture

c) isolated right ventricular shock

d) all of the above

Correct Answer - D

Answer : D> All of the above

Left ventricular dysfunction (LVD) - Most frequent cause of cardiogenic shock

Followed by,

- Acute mitral valve regurgitation
- Ventricular septal defect
- Isolated right ventricular shock
- Tamponade/ cardiac rupture

247. Nitric oxide acts by increasing ?

a) BRCA 1

b) BRCA 2

c) Interleukin

d) cGMP

Correct Answer - D

Answer: D> cGMP

Nitric oxide diffuses to the surrounding smooth muscle cells, **increasing cGMP** .

Cyclic guanosine monophosphate (cGMP)

Cyclic nucleotide derived from guanosine triphosphate (GTP).

Function:

- cGMP acts as a second messenger much like cyclic AMP.

Mechanism of action:

- Activation of intracellular protein kinases in response to the binding of membrane-impermeable peptide hormones.

248. Positive acid schiff macrophages seen in ?

a) Whipples disease

b) Crohns disease

c) AIDS

d) None of the above

Correct Answer - A

Answer : A> Whipples disease.

The traditional laboratory diagnosis is based on light microscopy, which shows diastase-resistant, periodic acid-**Schiff** (PAS)-positive, non-**acid-fast** granules in The distinction could be made by **acid-fast staining**, which is positive for patients infected with M. avium and negative for those with **Whipple's disease**.

249. A boy presented with multiple non suppurative osteomyelitis with sickle cell anaemia. What will be the causative organism?

a) Salmonella

b) S. aureus

c) H. influenzae

d) Enterobacter species

Correct Answer - A

Ans. A. Salmonella

Following are the various micro -organism involved in osteomyelitis

Age group	Most common organisms
Newborns (younger than 4 mo)	S. aureus, Enterobacter species, and group A and B Streptococcus species
Children (aged 4 mo to 4 y)	S. aureus, group A Streptococcus species, Haemophilus influenzae, and Enterobacter species
Children, adolescents (aged 4 y to adult)	S. aureus (80%), group A Streptococcus species, H. influenzae, and Enterobacter species
Adult	S. aureus and occasionally Enterobacter or Streptococcus species
Sickle cell anemia patients	Salmonella species are most common in patients with sickle cell disease

250. Term pathology refers to:

a) Work

b) Function

c) Details

d) Explains

Correct Answer - A

Ans. A. Work

Pathology is the medical term for the way a disease works.

The science of the causes and effects of diseases, especially the branch of medicine that deals with the laboratory examination of samples of body tissue for diagnostic or forensic purposes.

251. 1 yr child weighing 6 kg is suffering from Acute Gastroenteritis along with signs of sunken eyes & skin pinch going back to normal very rapidly. What will be your management?

- a) RL infusion 120 ml in the first hour followed by 360 ml in the next 5 hours
- b) RL INFUSION 180 ml in the first hour followed by 420 ml in the next 5 hours
- c) RL INFUSION 180 ML IN the first hour followed by 480 ml in the next 5 hours
- d) RL INFUSION 240 ml in the first hour followed by 360 ml in the next 5 hours

Correct Answer - B

Ans. B. RL INFUSION 180 ml in the first hour followed by 420 ml in the next 5 hours

Severe dehydration constitutes a medical emergency requiring immediate resuscitation with intravenous fluids.

Intravenous access should be obtained, and patients should be administered a bolus of 20-30 mL/kg lactated Ringer's (LR) or normal saline (NS).

If pulse, perfusion, and/or mental status do not improve, a second bolus should be administered.

After this, the patient should be given an infusion of 70 mL/kg LR or NS over 5 hours (children < 12 months) or 2.5 hours (older children).

If no peripheral veins are available, an intraosseous line should be placed. Serum electrolytes, bicarbonate, urea/creatinine, and

glucose levels should be sent.

252. What constitutes malpighian layer?

- a) Corneum lucidum
- b) Corneum spinosum
- c) Spinosum and basale
- d) Basale granulosum

Correct Answer - C

Ans.C.Spinosum and basale

The Malpighian layer of the skin is generally defined as both the stratum basale and stratum spinosum as a unit, although it is occasionally defined as the stratum basale specifically, or the stratum spinosum specifically. It is named after Marcello Malpighi.

253. Mechanism of action colchicine in acute gout

- a) Uric acid nephrolithiasis
- b) Deficiency of enzyme Xanthine oxidase
- c) Increase in serum urate concentration
- d) Renal disease involving interstitial tissues

Correct Answer - B

Ans.B.Deficiency of enzyme Xanthine oxidase.

Gout is a hereditary disorder with **increase in serum uric acid** due to increased production, or decreased excretion of uric acid and uric salt.

Thought to be caused by lack of an enzyme needed to completely metabolise purines for renal excretion.

Table 1. Metabolic Risk Factors for Gout

Obesity, eating 13w-1nel-rich foods (high levels of meat and seafood consumption)

Excessive alcohol intake

Metabolic syndrome

- Obesity
- Hypertension
- Hyperlipidemia
- Hyperglycemia
- Type 2 diabetes mellitus
- Hypertension
- Hyperlipidemia
- Serum urate—elevating medications
- History of urolithiasis

Chronic kidney disease, glomerular, or interstitial renal disease;
polycystic kidney disease

Potential genetic or acquired cause of uric acid overproduction,
including malignancy

Lead, or heavy-metal intoxication

254. Oxygen therapy may not be useful in

a) Asthma

b) Pneumonia

c) Subglottic stenosis

d) Pulmonary fibrosis

Correct Answer - D

Ans: D.Pulmonary fibrosis

Many EMS protocols indicate that oxygen should not be withheld from any patient, while other protocols are more specific or circumspect. However, there are certain situations in which oxygen therapy is known to have a negative impact on a patient's condition like paraquat poisoning, pulmonary fibrosis and lung damage resulting from bleomycin treatment.

255. New born baby with heart rate less than 60 beats per minute can be resuscitated by all except

a) chest compression

b) oxygen therapy

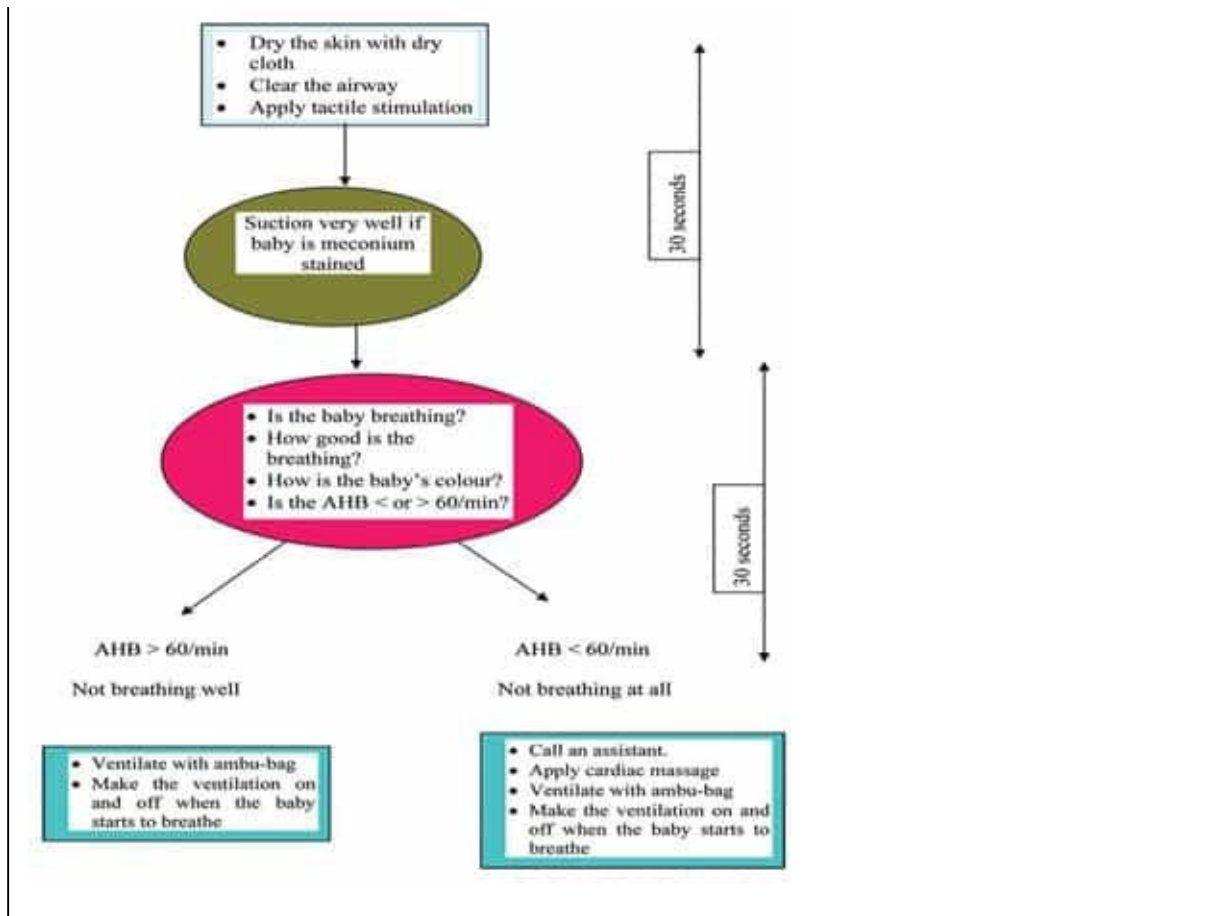
c) tactile stimulation

d) slapping the back

Correct Answer - D

Ans: D.slapping the back

The first three s are indicated while slapping the back is not recommended in a newborn who has Heart rate less than 60 beats per minute.



256. Mobitz type 2 second degree AV block is seen in all except:

- a) Hypothyroidism
- b) Coronary Artery Disease
- c) Sarcoidosis
- d) Cushing syndrome

Correct Answer - D

Ans: D. Cushing syndrome

Delay or lack of conduction through the atrioventricular (AV) node and below has multiple causes. Degenerative changes (eg, fibrosis, calcification, or infiltration) are the most common cause of non-ischemic AV block. Idiopathic fibrosis or calcification of the AV conduction system, commonly seen in the elderly, can cause complete AV block.

Causes of Mobitz type 2 second degree AV block are -

- Damage of the conduction system from coronary artery disease, valve surgery, myocardial infarction, myocarditis, infiltrative cardiomyopathies (sarcoidosis, hemochromatosis), myxedema, Lyme disease, neuromuscular disease, and AV junction ablation [6]

257. When can one diagnose acute respiratory distress in a child ?

a) Within 7 days of known clinical insult

b) Respiratory failure not fully explained

c) Left ventricular dysfunction

d) All of the above

Correct Answer - D

Ans: D. All of the above

Pediatric Critical Care Medicine 2015

Age	Exclude patients with 1:m11-natal related lung disease		
Timing	Within 7 days of known clinical Insult		
origin of Edema	Respiratory failure not fully explained by cardiac failure or fluid overload Chest		
Chest Imaging	imaging findings of new infiltrate(s) consistent with acute pulmonary		
	Non invasive mechanical ventilation or invasive mechanical ventilation-		
	PARDS (No severity gratification)	Mild	Moderate Severe
Oxygenation	Full face-mask bi-level ventilation or CPAP ≥ 5 cm H ₂ O	4501c8	EK 01 < 01 t16
	PF ratios 300	Ss09.c7.517.5 OSI	CiSt 1233
	SF ratio 5 2E4 I		<12.31

Special Populations

Standard Criteria above for age, timing, origin of edema

Cyanotic Heart Disease	and chest imaging with an acute deterioration In oxygenation not explained by underlying cardiac disease.
Chronic Lung Disease	standard Criteria above for age, timing, and origin of edema with chest imaging consistent with new infiltrate and acute deterioration in oxygenation from baseline which meet oxygenation criteria above_
Left Ventricular dysfunction	Standard Criteria for age, timing and origin of edema with chest imaging changes consistent with new infiltrate and acute deterioration in oxygenation which meet criteria above not explained by left ventricular dysfunction.

**258. A 6-year-old boy experienced life threatening shock ,his CT scan showed large amount of ascites, bowel wall thickening and poor or absent enhancement of the strangulated bowel segment, showing gangrenous bowel on surgical exploration.
True about anastomosis is-**

- a) Should be done by continuous layers as it takes less time
- b) Should be Done with catgut
- c) Should be Done by single layer seromuscular lembert sutures
- d) Should be Done by Single layer taking submucosa

Correct Answer - C

Ans C. Should be Done by single layer seromuscular lembert sutures

Diagnosis is of congenital IH with strangulated small bowel with gangrenous small bowel

Transmesenteric hernia was the most common type in older children as well as in neonates .

IH results from incomplete closure of surgically created mesenteric defects, and usually acquired resulting from previous abdominal surgery especially Roux-en-Y anastomosis

Anastomosis should be done by single layer seromuscular lembert sutures

The Lambert suture generally is used in abdominal surgery. It is an inverting suture, that can be either continuous or interrupted, used to

join two segments of an intestine without entering the lumen (the inner channel through which stomach contents flow).

259. In ACLS which drug can be given following ventricular fibrillation after cardiac arrest other than epinephrine?

a) Amiodarone

b) Dopamine

c) Adenosine

d) Atropine

Correct Answer - A

Ans. A. Amiodarone

V-Fib or VF is the most common rhythm that occurs immediately after cardiac arrest. In this rhythm, the heart beats with rapid, erratic electrical impulses.

Treatment:

- Shock / Defibrillation: every 2 minutes in a single one shock, successive, shockable increments
- 200 joules - Followed by immediate CPR for 2 minutes / give and circulate a drug(s)
- 300 joules - Followed by immediate CPR for 2 minutes / give and circulate a drug(s)
- 360 joules - Followed by immediate CPR for 2 minutes / give and circulate a drug(s)

Drugs :

- Give Epinephrine 1mg of a 1:10,000 solution every 3 to 5 minutes [No Limit]

Give either:

- Amiodarone [if not contraindicated, can be given 2x]: 300mg first dose / 150mg second dose at 3 to 5 minutes increments.

- Lidocaine: First dose: 1mg/kg or 1.5 mg/kg. Can repeat it at half the original dose up to a total of 3 mg/kg [Second and remaining doses are given at either 0.5mg/kg or 0.75mg/kg depending on your starting dosage.]

260. Which of the following statement is false about MR vaccination campaign launched by WHO?

- a) Children from 9 months to less than 15 vaccinated
- b) Congenital rubella syndrome (CRS), responsible for irreversible birth defects
- c) India has not yet launched this campaign
- d) Will replace routine immunization for measles vaccine

Correct Answer - C

Answer: C. India has not yet launched this campaign

One of the world's largest vaccination campaign against measles, a major childhood killer disease, and congenital rubella syndrome (CRS), responsible for irreversible birth defects.

India, along with ten other WHO South East Asia Region member countries, have resolved to eliminate measles and control rubella/congenital rubella syndrome (CRS) by 2020

All children from 9 months to less than 15 years of age will be given a single shot of Measles-Rubella (MR) vaccination during the campaign

Following the campaign, MR vaccine will become a part of routine immunization and will replace measles vaccine, currently given at 9-12 months and 16-24 months of age of child.

For those children who have already received such vaccination, the campaign dose would provide additional boosting to them.

261. Which of the following true regarding Hemophilia A

- a) Serum levels of factor VIII are decreased
- b) Deficiency of factor IX
- c) PT increased
- d) FIT decreased

Correct Answer - A

Answer: A. Serum levels of factor VIII are decreased

Hemophilia is an X linked disorder of coagulation caused by the deficiency in a circulating plasma protein. Hemophilia A is caused by the deficiency of factor VIII, and hemophilia B is caused by the deficiency of factor IX.

It is PTT which is affected (increased) and not PT (unaffected).

Factor VIII is involved in the intrinsic pathway which is measured by PTT and not in extrinsic pathway which is measured as PT.

Bleeding is the common manifestation of hemophilia and the common bleeding manifestations are hemarthroses, hematomas, mucocutaneous bleeding, intracranial bleeding, hematuria and pseudotumor.

262. Marked bleeding is seen in which of following conditions?

a) VMA disease

b) Haemophilia A

c) Haemophilia B

d) ALL

Correct Answer - D

Answer: D. ALL

Bleeding disorders can be inherited or acquired. Inherited disorders are passed down through genetics. Acquired disorders can develop or spontaneously occur later in life. Some bleeding disorders can result in severe bleeding following an accident or injury. In other disorders, heavy bleeding can happen suddenly and for no reason. There are numerous different bleeding disorders, but the following are the most common ones:

Hemophilia A and B are conditions that occur when there are low levels of clotting factors in your blood. It causes heavy or unusual bleeding into the joints. Though hemophilia is rare, it can have life-threatening complications.

Factor II, V, VII, X, or XII deficiencies are bleeding disorders related to blood clotting problems or abnormal bleeding problems. **von Willebrand's disease** is the most common inherited bleeding disorder. It develops when the blood lacks von Willebrand factor, which helps the blood to clot.

263. Reed sternberg cells are found in

a) Hodgkin's disease

b) Sickle cell anaemia

c) Thalassemia

d) CML

Correct Answer - A

- Reed Sternberg cells are you derived from B lymphocytes, classically considered crippled germinal center B cells, Seen against a sea of B cells which give the tissue a moth-eaten appearance.
- They are large and are either multinucleated or have a bibbed nucleus (thus resembling an "owl's eye" appearance) with prominent eosinophilic inclusion-like nucleoli.
- They are CD30 and CD15 positive, usually negative for CD20 and CD45.
- The presence of these cells is necessary for the diagnosis of Hodgkin's lymphoma - the absence of Reed-Sternberg cells has very high negative predictive value.
- They can also be found in reactive lymphadenopathy (such as infectious mononucleosis, carbamazepine associated lymphadenopathy) and very often in other types of non-Hodgkin lymphomas.

264. By which method foreign DNA is introduced into a cell by a virus or viral vector?

a) Transduction

b) Transcription

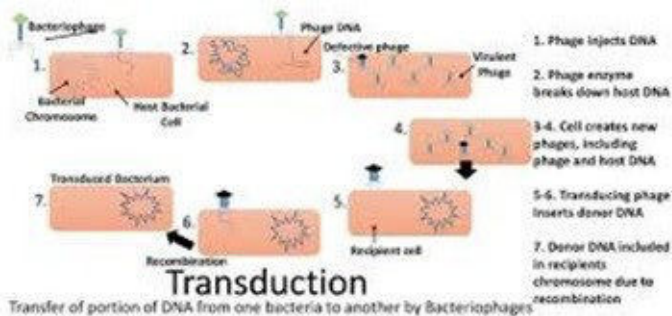
c) Lysogenic conversion

d) Transformation

Correct Answer - A

Ans. A. Transduction

Transduction is the process by which foreign DNA is introduced into a cell by a virus or viral vector. An example is the viral transfer of DNA from one bacterium to another.



265. Which one of the following shows allosteric inhibition?

a) Malonic acid & succinate

b) 2,3 BPG

c) Amino acid alanine & pyruvate kinase

d) Citrate

Correct Answer - B

Answer: B. 2,3 BPG

Negative **allosteric** modulation (also known as **allosteric inhibition**) occurs when the binding of one ligand decreases the affinity for substrate at other active sites. For **example**, when 2,3-BPG binds to an **allosteric** site on hemoglobin, the affinity for oxygen of all subunits decreases.

266. Which of the following is seen in seropositive rheumatoid arthritis?

a) Multiple joints affected

b) Symmetrical joint symptoms

c) Joint pain and swelling

d) All

Correct Answer - D

Answer: D. All

Positive for Rheumatoid factor in blood is seropositivity.

Patients with positive rheumatoid factor usually present with symptoms like

- **Joint deformities & disability**
- **Symmetrical involvement of joints**
- **Inflammation**
- **Swelling and painful in multiple joints**, especially of hands and feet.
- Morning stiffness (short term)
- Development of firm lumps near joints - "**Rheumatoid nodules**"
- Deterioration of bone & cartilage (X- ray findings)

267. Which of the following is not seen in Anterior mediastinum

a) Thyroid tumour

b) Thymoma

c) Lymphoma

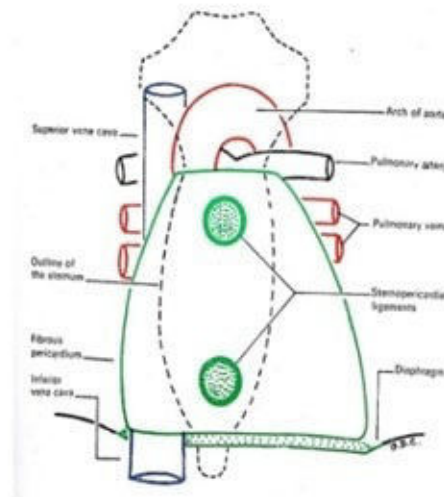
d) Neurogenic tumor

Correct Answer - D

Answer: D. Neurogenic tumor

Anterior Mediastinum: Contents

- Thymus (Children)
- Sternopericardial ligaments
- Internal thoracic artery & branches
- Lymphatics & Lymph nodes



28

The anterior mediastinum is the portion of the mediastinum anterior to the pericardium and below the thoracic plane. It forms the anterior part of the inferior mediastinum and contains the thymus, lymph nodes, and may contain the portions of a retrosternal thyroid.

Mediastinal Tumors and Other Masses

Superior Mediastinum	Anterior Mediastinum	Posterior Mediastinum	Middle Mediastinum
Lymphoma	Thymoma	Neurogenic tumors	Bronchogenic cyst
Thymoma	Teratoma	Lymphoma	Pericardial cyst
Thyroid lesions	Lymphoma	Gastroenteric hernia	Lymphoma
Metastatic carcinoma	Thyroid lesions		
Parathyroid tumors	Parathyroid tumors		

268. Struvite stone is caused by which metal?

a) Magnesium

b) Calcium

c) sodium & potassium

d) both (a) & (b)

Correct Answer - A

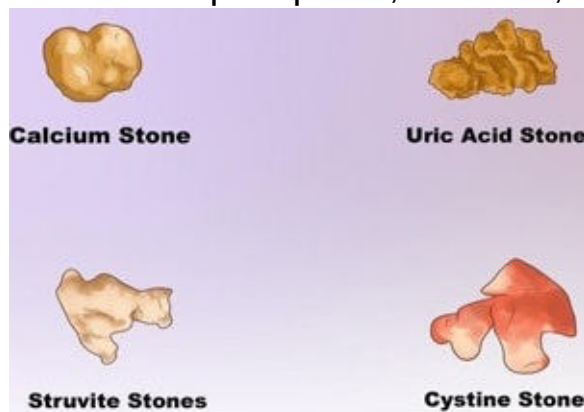
Ans. A. Magnesium

Struvite, a crystalline substance is composed of magnesium ammonium phosphate ($\text{MgNH}_4\text{PO}_4 \cdot 6\text{H}_2\text{O}$).

Struvite urinary stones have also been referred to as “infection stones” and “triple phosphate” stones.

Struvite stones can be **caused** by alkaline urine, steroid therapy, abnormal retention of urine, a urinary tract infection, or another disorder of the urinary tract.

There are five primary types of commonly encountered urinary stones, i.e., calcium oxalate, calcium phosphate, magnesium ammonium phosphate, uric acid, and cystine.



269. Which of the following statements about Graves disease is false?

- a) Results in hyperthyroidism
- b) Autoimmune disorder
- c) Common in Male
- d) Referred as Toxic diffuse goitre

Correct Answer - C

Ans. C - Common in male

Graves' disease:

- **Autoimmune** system disorder
- Both men and women get affected;
- Yet, **10 times more common in women than men**
- Affects younger women < 40 years
- Results in overproduction of thyroid hormones (**hyperthyroidism**).

Signs and symptoms:

- Anxiety
- Irritability
- Heat sensitivity
- Increased perspiration/ warm and moist skin
- Weight loss
- **Goiter (Glandular enlargement)**
- Menstrual cycle changes
- Erectile dysfunction/ reduced libido
- Graves **Ophthalmopathy** - Bulging eyes - **Exophthalmos**
- **Graves dermopathy** - Thick, red skin on shins / top of feet.
- **Antibody for graves disease - Thyrotropin receptor antibody (TRAb) acts on the** regulatory pituitary hormone interfering the normal secretion of thyroxine.

- TRAb overrides normal regulation causing an **overproduction of thyroid hormones (hyperthyroidism)**.

270. Aldosterone synthesis is stimulated by which of the following?

a) ACTH

b) Hyperkalemia

c) Hyponatremia

d) Exogenous steroids

Correct Answer - B

Ans. B. Hyperkalemia

Mineralocorticoid secretion is stimulated by hyperkalemia, angiotensin-II, ACTH and hyponatremia, in reducing order of efficacy.

1. Aldosterone secretion in response to hyperkalemia is the most important and forms the basis for renal regulation of body potassium balance.
2. Stimulation of aldosterone by angiotensin II (through the renin-angiotensin system) is important for the correction of hypovolemia and hypotension in conditions like salt depletion or renal ischemia.
3. Stimulation of aldosterone secretion by ACTH results in diurnal variation of aldosterone secretion. However, ACTH is not an important physiological regulator for aldosterone secretion.
4. Hyponatremia is a weak stimulator of aldosterone secretion

271. Which of the following is false about Alzheimer's disease?

- a) One in 10 people age 65 and older has Alzheimer's disease
- b) Alzheimer's disease is curable
- c) Cause dementia
- d) All of the above

Correct Answer - B

Ans. B. Alzheimer's disease is curable

Alzheimer's disease Also called: **senile dementia**. A progressive disease that destroys memory and other important mental functions.

Memory loss and confusion are the main symptoms.

Currently, there is no **cure** for **Alzheimer's**. But drug and non-drug treatments may help with both cognitive and behavioral symptoms.

The treatments available for Alzheimer's do not slow or stop the progression of the disease, but they may help with the symptoms for a time.

There are three cholinesterase inhibitors to treat Alzheimer's:

- Donepezil (Aricept)
- Rivastigmine (Exelon)
- Galantamine (Reminyl)

People may experience:

- **Cognitive:** mental decline, difficulty thinking and understanding, confusion in the evening hours, delusion, disorientation, forgetfulness, making things up, mental confusion, difficulty concentrating, inability to create new memories, inability to do simple maths, or inability to recognise common things
- **Behavioural:** aggression, agitation, difficulty with self care,

- irritability, meaningless repetition of own words, personality changes, restlessness, lack of restraint, or wandering and getting lost
- **Mood:** anger, apathy, general discontent, loneliness, or mood swings
 - **Psychological:** depression, hallucination, or paranoia
- Also common:** behavioral symptoms, inability to combine muscle movements, jumbled speech, or loss of appetite

272. Which of the following is true about vitamin K?

- a) Anticoagulant
- b) Prolong use of antimicrobial leads to deficiency
- c) Dietary allowance is 15-20 mg
- d) All of the above

Correct Answer - B

Ans. B. Prolong use of antimicrobial leads to deficiency

Certain people are at increased risk if they:

- take coumarin anticoagulants such as [warfarin](#), which thins the blood
- are taking **antibiotics**
- have a condition that causes the body to not absorb fat properly (fat malabsorption)
- have a diet that is extremely lacking in vitamin K

Vitamin K is a group of structurally similar, fat-soluble vitamins the human body requires for complete synthesis of certain proteins that are prerequisites for blood coagulation and which the body also needs for controlling binding of calcium in bones and other tissues. The body needs vitamin K to produce prothrombin, a protein and clotting factor that is important in blood clotting and bone metabolism.

Without vitamin K, blood coagulation is seriously impaired, and uncontrolled bleeding occurs. Preliminary [clinical research](#) indicates that deficiency of vitamin K may weaken bones, potentially leading to osteoporosis, and may promote calcification of arteries and other soft tissues

Dietary allowance for adults per day- 50-100 mg.

273. Which drugs needs continuous monitoring of prothrombin time?

a) Aspirin

b) Lepirudin

c) Digoxin

d) Coumadin

Correct Answer - D

Ans. D. Coumadin

Coumadin (warfarin) is an anticoagulant.

Warfarin is a coumarin anticoagulant used for the prophylaxis and treatment of thromboembolic complications associated with cardiac valve replacement and atrial fibrillation, as well as the prophylaxis and treatment of venous thrombosis and pulmonary embolism. Increased metabolism of warfarin results in insufficient prolongation of prothrombin time.

274. Which of the following are the risk factor for cutaneous lymphoma?

a) Age

b) Gender

c) Weakened immune system

d) All

Correct Answer - D

Answer: D . All

Risk Factors for Lymphoma of the Skin

Age Age is an important risk factor for this disease, with most cases occurring in people in their 50s and 60s. But some types of skin lymphoma can appear in younger people, even in children.

Gender and race Most (but not all) types of skin lymphoma are more common in men than in women. Most also tend to be more common in African-Americans than in whites. The reasons for this are not known.

Weakened immune system Skin lymphomas may be more common in people with acquired immunodeficiency syndrome (AIDS), who have a weakened immune system. They may also be more common in people who have had an organ transplant such as a heart, kidney or liver transplant. These people must take drugs that suppress their immune system, which may raise the risk of skin lymphoma (or lymphomas in other parts of the body).

Infections Infection with the human immunodeficiency virus (HIV), the virus that causes AIDS, may increase a person's risk of skin lymphoma.

275. Which is not included in AIDS related complex?

- a) Ectopic pregnancy
- b) Recurrent genital candidiasis
- c) Generalised lymphadenopathy
- d) Chronic diarrhea

Correct Answer - A

Answer- A. Ectopic pregnancy

HIV symptoms: AIDS related complex (ARC)

It belongs to class B of HIV symptoms. The patients at this stage have various diseases that occur because the HI virus has weakened the immune system.

The following HIV signs may have patients with ARC:

- Long-lasting diarrhea (over four weeks)
- Unintended heavy weight loss
- Long lasting fever
- Night sweats
- Bacterial infections caused by bacteria
- Bacterial blood poisoning (sepsis)
- Phthisis
- Herpes zoster
- Oral hairy leukoplakia (whitish changes on the lateral tongue border)
- Fungi caused by fungi
- HIV symptoms – Women: vaginal inflammation caused by fungi, malignant changes in the cervix

276. Which is the treatment of choice for irradiation in Chordoma?

a) Protons

b) Electrons

c) Gamma radiation

d) 3D - CRT

Correct Answer - A

Answer: A - Proton Therapy

Chordoma:

- Slow-growing neoplasm
- Arising from cellular remnants of notochord.
- Arise from bone in skull base and along spinal cord.

Most common locations -

- Cranially at clivus
- In sacrum at bottom of spine

Radiation therapy:

- Are relatively radioresistant
- High doses of radiation required to control.
- Hence, high focus radiation like proton therapy and carbon ion therapy are preferred than conventional radiation methods.
- Close proximity to vital structures like brain stem, requires high precision and accuracy for any planned surgical resection.
- Radiation with high accuracy and minimal damage with maximal safety is delivered.

277. What differentiates delirium from dementia?

- a) Confusion
- b) Difficulty in communicating
- c) Hallucination
- d) Sudden change

Correct Answer - D

Answer: D. Sudden change

Delirium

- Also called the acute confusional state, delirium is a medical condition that results in confusion and other disruptions in thinking and behavior, including changes in perception, attention, mood and activity level.
- In **dementia**, changes in memory and intellect are slowly evident over months or years. Delirium is a more abrupt confusion, emerging over days or weeks, and represents a **sudden change** from the person's previous course of dementia. Thinking becomes more disorganized, and maintaining a coherent conversation may not be possible.
- The hallmark separating delirium from underlying dementia is inattention. The individual simply cannot focus on one idea or task.

278. Genital warts are caused by which virus?

a) Herpes simplex

b) Human papilloma

c) Cytomegalovirus

d) Varicella zoster

Correct Answer - B

Ans. B. Human papilloma

Genital warts are soft growths that appear on the genitals. **Genital warts** are a sexually transmitted infection (STI) caused by certain strains of the human papillomavirus (HPV). These skin growths can cause pain, discomfort, and itching.

279. Which drug regimen is given in a pregnant woman with HIV infection?

a) Tenofovir disoproxil fumarate with emtricitabine

b) Tenofovir disoproxil fumarate with lamivudine

c) Abacavir with lamivudine

d) All

Correct Answer - D

Ans. D. All

Preferred Regimens for HIV Antiretroviral Therapy (ART) in Pregnancy

Two-NRTI backbone

Regimens include the following:

- Tenofovir disoproxil fumarate with emtricitabine (TDF/FTC co-formulated) or tenofovir disoproxil fumarate with lamivudine (3TC) once daily (use with caution in renal insufficiency) or
- Abacavir with lamivudine (ABC/3TC) once daily (only if HLA-B5701–negative); avoid combination with ritonavir-boosted atazanavir if the pretreatment HIV viral load exceeds 100,000 copies/mL.
- For women who have never taken HIV medicines, the preferred HIV regimen should include two **nucleoside reverse transcriptase inhibitors (NRTIs)** plus an **integrase strand transfer inhibitor (INSTI)**, a **non-nucleoside reverse transcriptase inhibitor (NNRTI)**, or a **protease inhibitor (PI)** with low-dose **ritonavir** (brand name: Norvir).

The regimen generally should include at least one of the following NRTIs that pass easily across the placenta:

- **abacavir** (brand name: Ziagen)
- **emtricitabine** (brand name: Emtriva)

- **lamivudine** (brand name: Epivir)
- **tenofovir disoproxil fumarate**(brand name: Viread)
- **zidovudine** (brand name: Retrovir)

280. Which of the following structure develops from dorsal mesentery?

a) Greater omentum

b) Lesser omentum

c) Liver

d) Diaphragm

Correct Answer - A

Ans. A. Greater omentum

The portion of the **dorsal mesentery** that attaches to the greater curvature of the stomach, is known as the dorsal mesogastrium. The part of the **dorsal mesentery** that suspends the colon is termed the mesocolon. The dorsal mesogastrium **develops** into the greater omentum.

281. Which of the following is the best Stent for Femoropopliteal Bypass?

a) Dacron

b) Reversed saphenous

c) PTFE

d) None

Correct Answer - C

Answer: C- PTFE-covered self-expanding nitinol stents

- PTFE-covered stents are engineered with a 30–100-micron pore size to allow for the endothelial lining of the stent-graft and vessel healing.
- The two main graft types used for lower extremity bypasses are the great saphenous veins and polytetrafluoroethylene (PTFE) grafts.
- One of the most widely used stent-grafts in the treatment of chronic lower extremity ischemia is the Viabahn endoprosthesis (Gore Medical, Flagstaff, Ariz).
- It is constructed with expanded polytetrafluoroethylene (ePTFE) liner attached to an external nitinol stent.
- The inner surface is bonded with heparin.

282. Trilene is degraded by:

a) Enzymatic Degradation

b) Non Enzymatic degradation

c) Chemical Degradation

d) None

Correct Answer - A

Answer: A. Enzymatic Degradation

Trilene or trichloroethylene is a good analgesic, less depressant, and non-flammable.

Cardiac dysrhythmia, or tachypnoea may occur during administration.

It should not be used in the closed circuit as it reacts with soda-lime to produce a toxic gas(phosgene).

Recovery is slow and nausea as well as vomiting may be present.

It should not be used with adrenaline infiltration lest dysrhythmia be converted to ventricular fibrillation.

Degradation:

- Brought about by enzymatic degradation
- The enzyme that starts one branch of this pathway, toluene 1,2-dioxygenase, has many other catalytic abilities, which are documented in a table of the Reactions of Toluene 1,2-Dioxygenase.
- The spontaneous degradation of trichloroethylene epoxide can produce as many as four products: dichloroacetate, carbon monoxide, glyoxylate, and formate. The number, type, and proportion of products seen depends on the local environment.

283. The earliest feature of 3rd cranial nerve involvement in diabetes mellitus patient is -

- a) Normal light reflex
- b) Abnormal light reflex
- c) Normal light and accommodation reflex
- d) Abnormal light and accommodation reflex

Correct Answer - A

Answer: A. Normal light reflex

The **oculomotor nerve** is the third cranial nerve. It enters the orbit via the superior orbital fissure and innervates muscles that enable most movements of the eye and that raise the eyelid. The nerve also contains fibers that innervate the muscles that enable pupillary constriction and accommodation (ability to focus on near objects as in reading). The oculomotor nerve is derived from the basal plate of the embryonic midbrain. In people with diabetes and older than 50 years of age, an oculomotor nerve palsy occurs.

284. During squint surgery, anesthesiologist sees the machine and see the bp suddenly drops to 40. What will be best immediate management -

- a) Give atropine
- b) Increase level of anesthesia
- c) Ask the surgeon to stop the surgery
- d) Give adrenaline

Correct Answer - D

Answer: D. Give adrenaline

Adrenaline should be given to raise the blood pressure.

Epinephrine, also known as adrenalin or adrenaline, is a [hormone](#), [neurotransmitter](#), and [medication](#). Epinephrine is normally produced by both the [adrenal glands](#) and certain [neurons](#).

It plays an important role in the [fight-or-flight response](#) by increasing blood flow to muscles, [output of the heart](#), [pupil dilation](#), and [blood sugar](#). It does this by binding to [alpha](#) and [beta receptors](#).

Physiologic responses to epinephrine by organ

Organ	Effects
Heart	Increases heart rate; contractility; conduction across AV node
Lungs	Increases respiratory rate; bronchodilation
Systemic	Vasoconstriction and vasodilation
Liver	Stimulates glycogenolysis

Systemic	Triggers lipolysis
Systemic	Muscle contraction

285. All are special visceral efferent column except -

a) Glossopharyngeal n

b) Nucleus ambiguus

c) vagus nerve

d) trigeminal nerve

Correct Answer - B

Answer: B. Nucleus ambiguus

Special visceral efferent fibers (SVE) are the efferent nerve fibers that provide motor innervation to the muscles of the pharyngeal arches in humans. The only nerves containing SVE fibers are cranial nerves: the trigeminal nerve (V), the facial nerve (VII), the glossopharyngeal nerve (IX), the vagus nerve (X) and the accessory nerve.

286. Which of the following condition is NOT caused by Parvovirus B19?

- a) Roseola infantum
- b) Aplastic anemia in sickle cell disease
- c) Fetal hydrops
- d) Erythema infectiosum

Correct Answer - A

Answer: A. Roseola infantum

Primary infection by **parvovirus B19** often produces an acute, severe, and sometimes fatal anemia manifested as a rapid fall in red blood cell count and hemoglobin.

These patients may present initially with no clinical symptoms other than fever; this is commonly referred to as **aplastic crisis**.

Erythema infectiosum (also referred to as fifth disease or academy rash) is a more common disease that is clearly attributable to parvovirus B19.

Active transplacental transmission of parvovirus B19 can occur during primary infections in the first 20 weeks of pregnancy, sometimes resulting in stillbirth of fetuses that are profoundly anemic.

The progress can be so severe that hypoxic damage to the heart, liver, and other tissues leads to extensive edema (hydrops fetalis).

287. Which of the following statements is not true about iliolumbar ligament?

- a) Upper fibres attached to iliac crest
- b) Lower fibres attached to base of sacrum
- c) Help in maintaining lumbosacral joint stability
- d) Upper attachment to transverse process of T12

Correct Answer - D

Answer: D - Upper attachment to transverse process of T12

The ligament attaches to L5

Iliolumbar ligament:

- Strong ligament passing from **the tip of transverse process of fifth lumbar vertebra** to posterior part of inner lip of iliac crest
- **Upper bands** gets **attached to the iliac crest.**
- **Lower bands** gets **attached to base of sacrum.**
- Major function is to **strengthen the lumbosacral joint.**

288. Where will be the placement location for Auditory Brainstem Implant?

- a) Scala tympani
- b) Recess of 4th ventricle
- c) IAC
- d) back of ear

Correct Answer - B

Answer: B - Recess of 4th ventricle.

The implant is usually placed in the lateral recess of the fourth ventricle at the time of tumor resection to stimulate the cochlear nucleus

Auditory Brainstem Implant (ABI):

- Tumor resection surgery in NF patients result in cochlear nerve damage or loss of function of nerve resulting in deafness.
- ABI are useful in restoring auditory perception to deaf patients with neurofibromatosis type 2 (NF2)
- Also used in treatment of congenitally deaf children with cochlear malformations or cochlear nerve deficiencies.
- Placement location: **Lateral recess of 4th ventricle**

289. Which condition is associated with Congenital adrenal hypoplasia?

- a) Male pseudohermaphroditism
- b) Female pseudohermaphroditism
- c) True pseudohermaphroditism
- d) Sequential pseudohermaphroditism

Correct Answer - B

Answer - B -

Congenital Adrenal Hyperplasia:

- This is the most common cause of androgenic excess in fetuses with female pseudohermaphroditism.
- The hyperplastic glands synthesize defective enzymes that cause impaired cortisol synthesis.
- This leads to excessive pituitary ACTH the secretion of the fetal adrenal glands with secretion of large amounts of cortisol precursors, including androgenic prehormones.
- These prehormones, for example, androstenedione, are converted to testosterone in fetal extra-adrenal tissues.

290. Which is true regarding ataxia telangiectasia:

- a) Increase in AFP
- b) Increases the risk of squamous cell carcinoma
- c) Autosomal dominant
- d) None of above

Correct Answer - A

Answer: A - Increase in AFP

Increase in alpha-fetoprotein is observed in Ataxia telangiectasia

Ataxia-telangiectasia / Ataxia-telangiectasia syndrome / **Louis-Bar syndrome**

Rare, **neurodegenerative, autosomal recessive disorder** causing severe disability.

Ataxia refers to poor coordination; Telangiectasia refers to small dilated blood vessels.

Parts affected:

- Cerebellum - movement & coordination difficulties
- Immune system - Predisposing to infections.
- Genetic repair system - Preventing process for repairing DNA - Cancer risk

Features:

- Increased incidence of **lymphoma & Leukemia**
- **Increased alpha-Fetoprotein levels**
- **Oculomotor apraxia** (difficulty in coordination between head & eye movements)
- Dysarthria

291. A diabetic patient 2 days after post cataract surgery develops develops hypopyon. What will be the management?

a) Intravitreal antibiotics

b) Eye drops

c) Surgery

d) No treatment required

Correct Answer - A

Ans. A. Intravitreal antibiotics

292.

What is the Thinnest part of neuro-retinal rim according to ISNT rule?

a) Inferior

b) Superficial

c) Temporal

d) Medial

Correct Answer - C

Ans. C. Temporal

The **ISNT rule** is an easy way to remember how the optic nerve is supposed to look in a normal eye. Normally the neuro-retinal rim is thickest Inferiorly and thinnest Temporally. With glaucoma, however, you begin to see vertical thinning, with atrophy along the inferior and superior rims.

293. Leiden thrombophilia is caused by mutational deficiency of which of the following factors?

a) Factor V

b) Factor VII

c) Factor IX

d) Factor X

Correct Answer - A

Ans. A. Factor V

Factor V Leiden thrombophilia is an inherited disorder of blood clotting. **Factor V Leiden** is the name of a specific **mutation** (genetic alteration) that results in thrombophilia, or an increased tendency to form abnormal blood clots in blood vessels. **Factor V Leiden** is the most **common** inherited form of thrombophilia.

294. Anteversion of uterus is maintained by?

- a) Cardinal ligament
- b) Uterosacral ligament
- c) Pubocervical ligament
- d) Round ligament

Correct Answer - D

Ans. D. Round ligament

In most women, the **uterus** is anteverted and anteflexed. The function of the round ligament is maintenance of the **anteversion** of the **uterus**(a position where the fundus of the **uterus** is turned forward at the junction of cervix and vagina) during pregnancy. Normally, the cardinal ligament is what supports the **uterine** angle (angle of **anteversion**).

295. Long-standing pelvic inflammation may lead to which of the following conditions?

a) Pyometra

b) Uterine polypsis

c) Pseudopregnancy

d) Cystic endometrial hyperplasia

Correct Answer - A

Ans. A. Pyometra

Pyometra is collection of pus due to obstruction of flow in the uterine cavity.

It may be due to Long-standing PID or secondary to cervical stenosis.