



collegebatch.com

click to campus

## NEET PG 2024 Question Paper with Answer

National Eligibility cum Entrance Test (Postgraduate)

Shift	Page No
NEET PG 2024 Question Paper with Answer - Shift 1	2 - 37
NEET PG 2024 Question Paper with Answer - Shift 2	38 - 47

Download more NEET PG Previous Year Question Papers: [Click Here](#)

## NEET PG 2024 Shift I Question Paper

---

**Ques 1. Male not responding to O<sub>2</sub>, diagnosis ARDS. What is the role of IL-8 in ARDS ?**

- A. Endothelial cell activation**
- B. Requirement of neutrophil**
- C. Macrophage activation**
- D. Promote surfactant production**

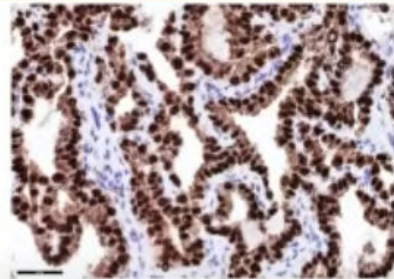
**Ans. B**

**Ques 2. A pt presents with the finding as shown, What is the best investigation for Wilson?**

- A. Urine Copper**
- B. Hepatic copper**
- C. S. Ceruloplasmin**
- D. MRI Brain**

**Ans. B**

**Ques 3. Which tumor is positive for TTF-1?**



- A. Sq**
- B. Small**
- C. Adeno Ca**
- D. Carcinoid**

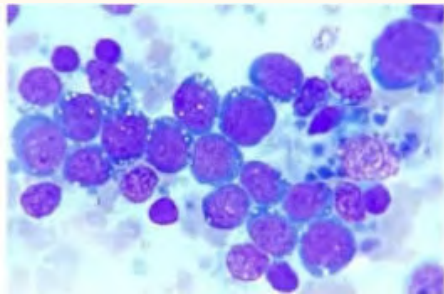
**Ans. C**

**Ques 4. Vitamin to be supplemented after gastrectomy?**

- A. Vit A**
- B. Vit C**
- C. Vit B12**
- D. Vit D**

**Ans. C**

**Ques 5. 10/m presents with CERVICAL L. node+, Surface Ig +, CD34-,5-, 23-, tdt -, cd 10+, 19+:**



- A. Burkitts Lymphoma**
- B. DLBCL**
- C. Anaplastic**
- D. B-ALL**

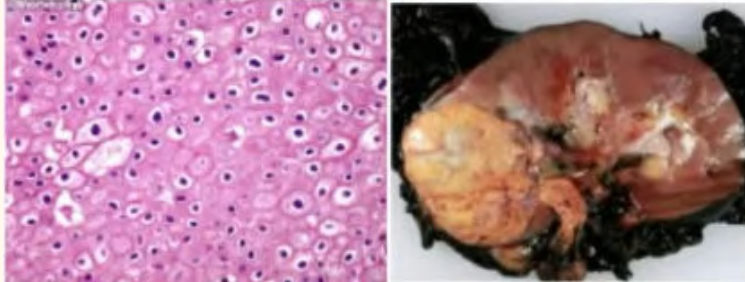
**Ans. A**

**Ques 6. Most common mutation in Papillary cell CA?**

- A. BRAF V600E**
- B. RET**
- C. MET**
- D. RAS**

**Ans. A**

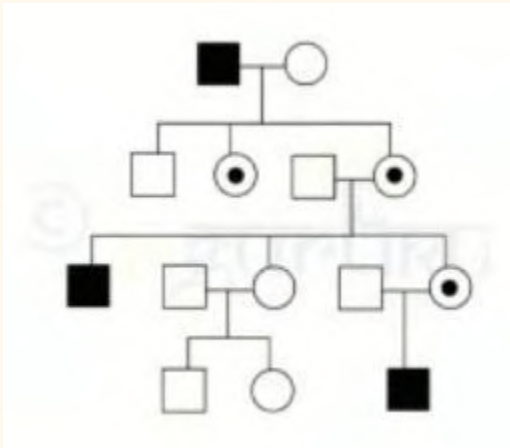
**Ques 7. Renal mass, haematuria, flank pain:**



- A. Clear cell**
- B. Papillary**
- C. Chromophobic**
- D. Belini**

**Ans. C**

**Ques 8. Which disease will show the following mode of inheritance?**



- A. Wiskott**
- B. Wilson**
- C. Prader willi**
- D. Achondroplasia**

**Ans. A**

**Ques 9. Young Male died during exercise. H/o of similar history in sibling, ON GROSS Morphology: septal thickening was seen. most common cause of death?**

- A. DCM**
- B. RCM**
- C. HOCM**
- D. Viral Myocarditis**

**Ans. C**

**Ques 10. 14. Which is not true?**

- A. Vwd type 1 is mostly severe ds in children**
- B. Vwd type 3 mostly severe ds in children**
- C. Vwd type 2 is more related activity rather than levels**
- D. Vwd type 3 has severely low VWD**

**Ans. A**

**Ques 11. Child Sun light causes eruptions, diagnosed as DNA repair defect, which defect it can?**

- A. Nucleotide excision**
- B. Base excision repair**
- C. Mismatch repair defect**
- D. Recombination defect**

**Ans. A**

**Ques 12. 18/ M Hepatosplenomegaly, Hb7gm%, LN+, WBC 50K, Plat 30, petiche, purpura, fatigue, what is most appropriate management?**

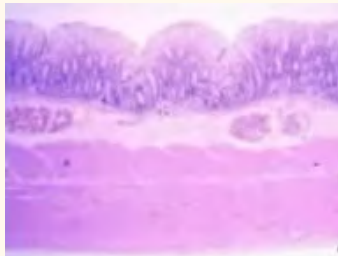
- A. Cytarabine + iso?**
- B. IVIG x 2days**

- C. Prednisolone+ Vinblastine
- D. Radiotherapy to LN

**Ans. C**

**Ques 13. A baby failed to passed meconium, the structures absent in the disease are absent in which of the following layer?**

- 1. Epithelial
- 2. Submucosa
- 3. Muscular
- 4. Serosa



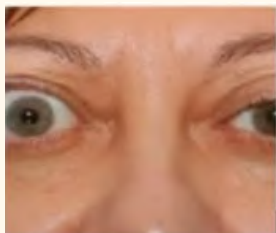**Select the correct answer from the given below cord:**

- A. 1 n 2
- B. 2 n3
- C. 3 n 4
- D. 1 n 4

**Ans. B**

**Ophthalmology**

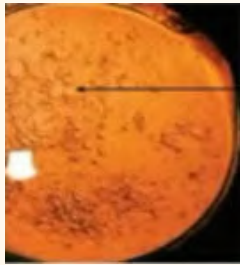**Ques 14. Muscle responsible for ptosis in Horner syndrome:-**



- A. Orbicularis oculi
- B. Levator palpebrae
- C. Horner muscle
- D. Mullers muscle

**Ans. D**

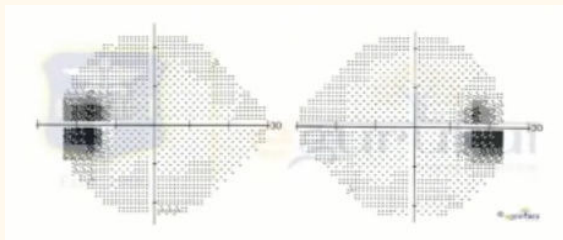
**Ques 15. A patient presented to eye Opd after 3 yrs of Cataract surgery. Slit lamp finding was given. What is the likely diagnosis?**



- A. PCO
- B. Bullous keratopathy
- C. Phakic glaucoma
- D. Lense subluxation

**Ans. A**

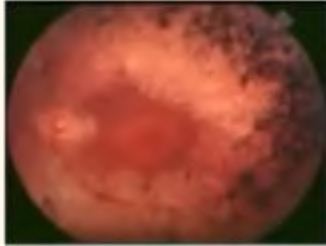
**Ques 16. Following perimetry image is suggestive of?**



- A. Extension of blind spot
- B. Arcuate scotoma
- C. Reinee step defect
- D. Altitude Anopia

**Ans. A**

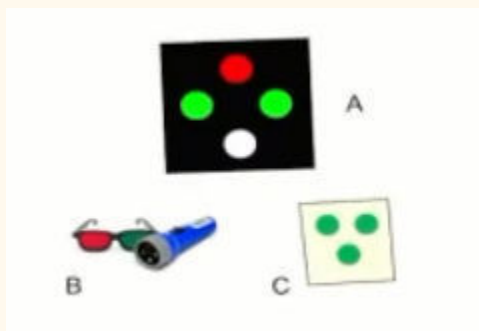
**Ques 17. 4. A patient Came with nyctalopia. Rational image given below what will be the diagnosis?**



- A. Retinitis pigmentosa**
- B. Vit A deficiency**
- C. Retinal detachment**
- D. Diabetic retinopathy**

**Ans. A**

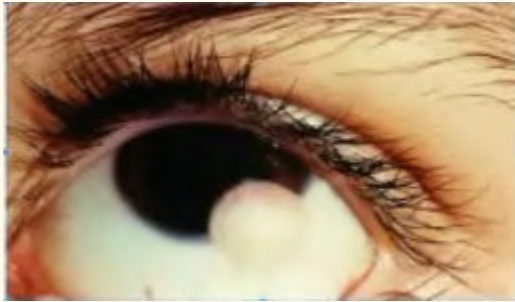**Ques 18. Patient was shown image A along with image B. Image C was visualised. Like diagnosis?**



- A. Lt eye suppression**
- B. Rt eye suppression**
- C. Crossed diplopia**
- D. Uncrossed diplopia**

**Ans. B**

**Ques 19. A patient present in eye opd with this finding what is:**



- A. Dermoid**
- B. Lipodermoid**
- C. Pterygium**
- D. Papilloma**

**Ans. A**

**Ques 20. . In Wilson disease. Best Choice of Investigation is?**

- A. Serum copper**
- B. Ceruloplasmin**
- C. Hepatic copper estimation**
- D. Urine copper**

**Ans. B**

**Ques 21. Clinical scenario about homocystinuria, which vitamin to be supplemented:**

- A. Thiamine**
- B. B6**
- C. Biotin**
- D. Pyruvate**

**Ans. B**

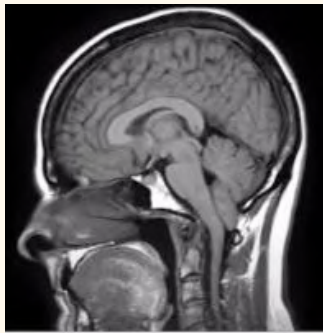
**Ques 22. A 2wk old baby presented with vomiting, acidosis, early cataract. Which of the following enzyme is defective:**

- A. Galactose 1 Po4 uridyl transference**
- B. Galactokinase**
- C. Hexokinase**
- D. Aldol reductase**

**Ans. A**

### **Radiology**

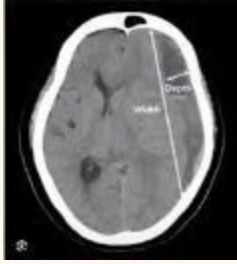
**Ques 23. Diagnosis of MRI image**



- A. Arnold chiari malformation**
- B. Corpus callosal agenesis**
- C. Vein of galen Malformation**
- D. Dandy Walker Malformation**

**Ans. A**

**Ques 24. A 76 year elderly patient presets in confused state. He is on antihypertensive medication and on aspirin due to previous heart attack. There is a minor traums due to fall from chair 3 weeks back. NCCT is done and show below. Diagnosis?**



- A. SAH
- B. EDH
- C. Normal Study
- D. Chronic SDH

**Ans. D**

**Ques 25. Diagnosis of MRCP image**



- A. GB Stone
- B. Cholangiocarcinoma
- C. Choledochal Cyst
- D. Gall and Blood Cancer

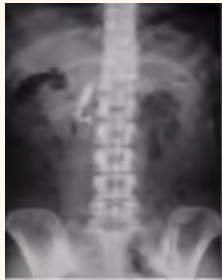**Ans. B**

**Ques 26. A 35 year old nullipara female presented with dull aching pain with exacerbation during menstrual cycle. Usg reveals a heterogenous mass in right adnexa. Mri reveals a 4 x 5 cm T1 hyperintense mass with no suppression on fat started images. T2 weighted images show low signal with Dark shading. Diagnosis?**

- A. Dermoid cyst**
- B. endometrioma**
- C. Ovarian cancer**
- D. Para Ovarian Cyst**

**Ans. B**

**Ques 27. Diagnosis of following Plain Xray of abdomen**



- A. Enterolith in jejunum**
- B. Calcific mediastinal lymph nodes**
- C. Horse shoe kidney with calculi**
- D. Chronic calcific pancreatitis**

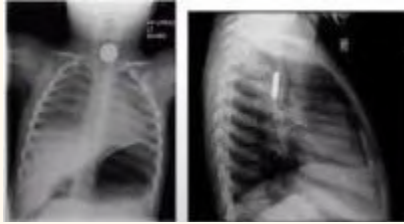**Ans. D**

**Ques 28. A patient has Proteus infection and now plain xray of abdomen was done and a large stone was shown in urinary bladder. Stone is made up of**

- A. Calcium Phosphate**
- B. Cysteine**
- C. Calcium Oxalate**
- D. Xanthine**

**Ans. A**

**Ques 29. Correct statement regarding esophageal FB**



- A. Right main bronchus is one of the site of constriction**
- B. Most common site of impaction is cricopharyngeus**
- C. Commonly seen in adults**
- D. Can't cause mediastinitis**

**Ans. B**

**Ques 30. Gastrectomy patient needs supplemental: (PART A)**

- A. Vit c**
- B. Vit d**
- C. Vit b12**
- D. Vit a**

**Ans. C**

**Ques 31. After a right limb amputation, the patient is experiencing severe pain phantom limb.**

**What is the mechanism behind this?**

- A. Projection of adjacent fibres to overlap to right sensory cortex**
- B. Projection of adjacent fibres to overlap to left sensory cortex**
- C. Expansion of right sensory cortex**
- D. Expansion of left sensory cortex**

**Ans. B**

**Ques 32. Patient had SUN BURN now takes bath 40 degree water, and feel pain**

- A. Thermal receptor :hyperalgesia.**
- B. Innocuous thermal receptor allodynia**
- C. Thermal receptor allodynia.**
- D. Innocuous thermal receptor hyperalgesia**

**Ans. B**

**Ques 33. A 50 yr old female presented with dyspnoea and chest pain. Which of the following proves that she has aortic stenosis then aortic regurgitation: (PART A) -**

- A. Increase in myocardial oxygen consumption is seen with increased pressure work than volume**
- B. Aortic stenosis causes reduced pressure at aortic valve**
- C. Workload has nothing to do with myocardial oxygen consumption**
- D. Increase in preload more than afterload than after load**

**Ans. A**

**Ques 34. Taste absent in which tastebud?**

- A. Filiform**
- B. Foliate**
- C. Fungiform Papilla Tash**
- D. Circumvallate**

**Ans. A**

**Ques 35. Which receptor helps in improvement of insulin resistance in DM2 with regular exercise and physical activity? (PART A) -**

- A. GLUT1**

- B. GLUT4**
- C. GLUT2**
- D. GLUT 3**

**Ans. B**

**Ques 36. A men having difficulty in sleep during night. He has habit of drinking coffee before bed time what is the role of caffeine in wakefulness:**

- A. Blocks adenosine action and cause wakefulness**
- B. Activates locus coeruleus and cause wakefulness**
- C. No role in maintaining wakefulness if taken 1hr before sleep**
- D. Activates histamine release and prevents sleep**

**Ans. A**

**Ques 37. RMP predominantly affected by which ion?**

- A. K<sup>+</sup>**
- B. Ca**
- C. Na**
- D. Cl**

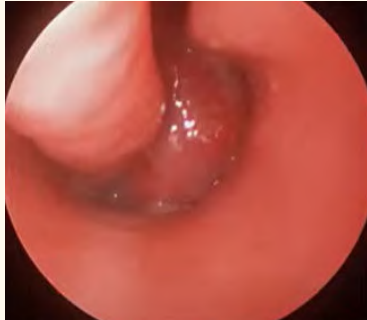**Ans. A**

**Ques 38. Alcoholic gait, nystagmus after RTA, which lobe of cerebellum is affected?**

- A. Flocculonodular**
- B. Dentate**
- C. Anterior lobe**
- D. Vermis**

**Ans. A**

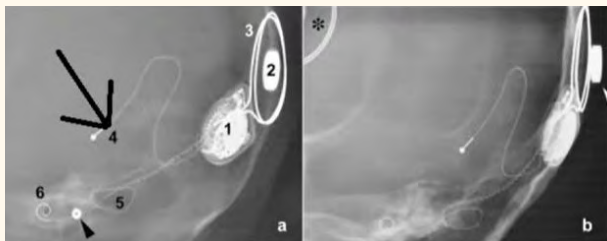
**Ques 39. A 14yr old boy presented with nasal mass and recurrent Estd. 1996 episodes of bleeding from the mass. Investigation of choice.**



- A. Plain CT**
- B. CT with contrast**
- C. X Ray Caldwell view**
- D. X Ray with Pierre view**

**Ans. B**

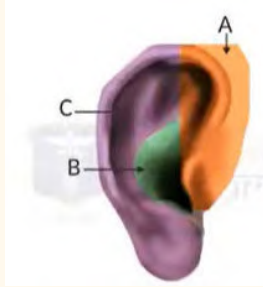
**Ques 40. Cochlear implant given below identify the marked structure:**



- A. Internal magnet**
- B. Electrode**
- C. Receiver**
- D. Antenna**

**Ans. B**

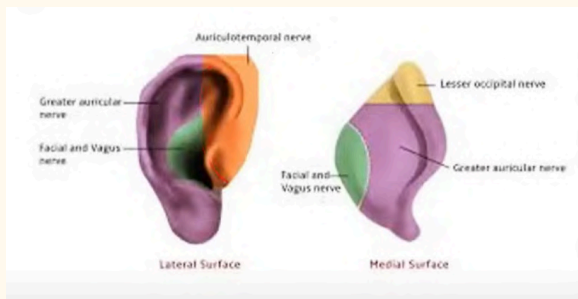
**Ques 41. Which nerve supplies the external ear?**



- A. ATN, greater auricular, 7 and 10
- B. Greater auricular, 7 and 10, ATN
- C. 7 and 10, ATN, greater auricular nerve
- D. ATN, 7 and 10, GAN

**Ans. D**

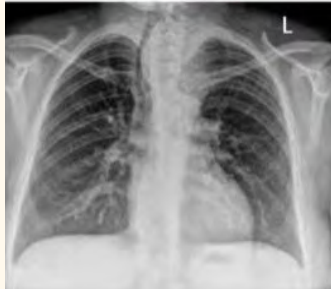**Ques 42. In head impulse test following finding seen in right vestibular neuritis:**



- A. On rotating head to right, left saccade
- B. On rotating head to left, right saccade
- C. On rotating head toward right, right saccade
- D. On rotating to the left, left saccade

**Ans. A**

**Ques 43. Which of the following instrument insertion will be difficult:**



- A. Nasogastric Tube**
- B. LMA**
- C. Tracheostomy**
- D. Indirect Laryngoscopy**

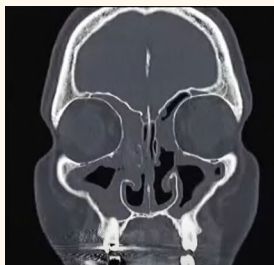**Ans. C**

**Ques 44. A singer presents with problem in high pitch. On examination bowing of one side vocal cord. Which of the following muscle is affected?**

- A. Posterior cricoarytenoid**
- B. Lateral cricoarytenoid**
- C. Cricothyroid**
- D. Thyroarytenoid**

**Ans. C**

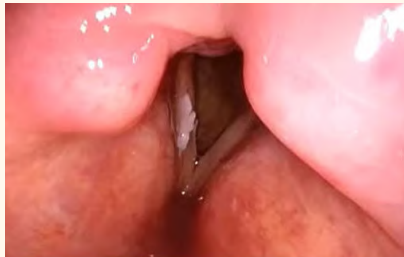**Ques 45. A 45-year-old male presents with breathlessness and undergoes a CT scan of the paranasal sinuses (PNS). Which sinus is obstructed ?**



- A. Maxillary**
- B. Frontal**
- C. Sphenoid**
- D. Ethmoid**

**Ans. A**

**Ques 46. Intraoperatively which stain is used to view following lesion:**



- A. AgNo<sub>3</sub>**
- B. Toluidine Blue**
- C. Congo red**
- D. Methylene blue**

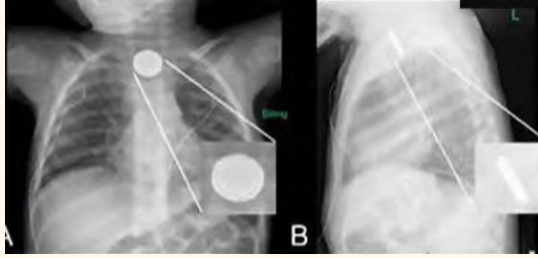
**Ans. B**

**Ques 47. Gag reflex will be absent in which nerve injury?**

- A. 5 and 10**
- B. 9 and 10**
- C. 10 and 12**
- D. 7 and 9**

**Ans. B**

**Ques 48. In given x-ray which of the following sign is seen:**



1. Double ring sign
2. String sign
3. Steeple sign
4. Thumb sign

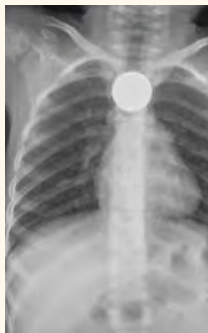**Ans. 1**

**Ques 49. Taste absent in which taste bud?**

- A. Filiform
- B. Foliate
- C. Papilla
- D. Circumvallate

**Ans. A**

**Ques 50. Which of the following may be true in this patient**

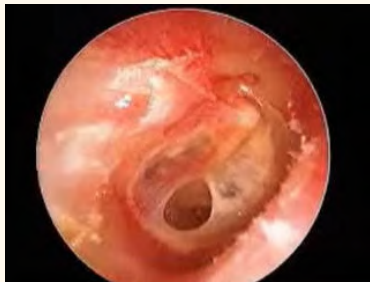

- A. Oesophagus is the correct site
- B. Most commonly in adult

- C. Mostly above cricoid
- D. Mediastinal infection not present

**Ans. A**

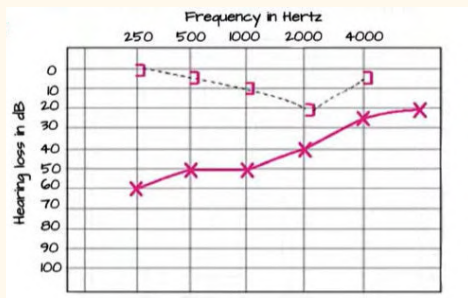
**Ques 51. A patient presented with c/o hearing loss and the otoscopy finding shown. What will be the Rinne test finding?**



- A. True positive
- B. True negative
- C. False positive
- D. False negative

**Ans. B**

**Ques 52. A Female with mild CHL and tinnitus. The PTA is shown. What is the interpretation.**

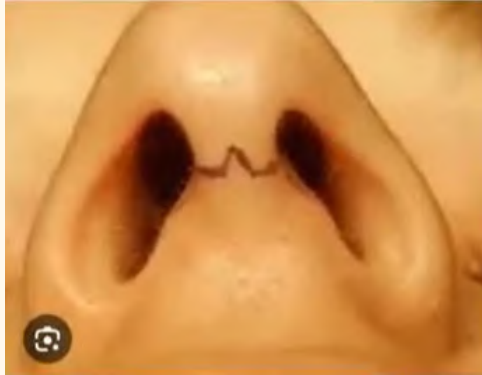


- A. Otosclerosis
- B. Meniere's disease

- C. NIHL
- D. None

**Ans. A**

**Ques 53. A nasal surgery was done in this patient and the incision mark is shown. Which of these is probably done?**



- A. Septoplasty
- B. Rhinoplasty
- C. FESS
- D. Young's surgery

**Ans. B**

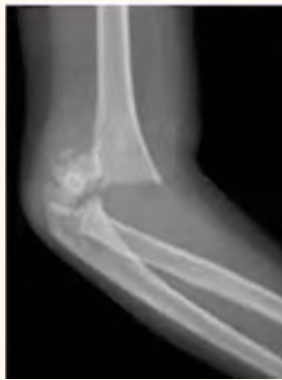**Ques 54. A man met to RTA come to emergency department with complaint of back pain. No Neurological deficit. X ray spine done what will be the diagnosis ?**



- A. Fracture of spinous process**
- B. Compressed fracture**
- C. Fracture of base of vertebrae**
- D. Chance fracture**

**Ans. D**

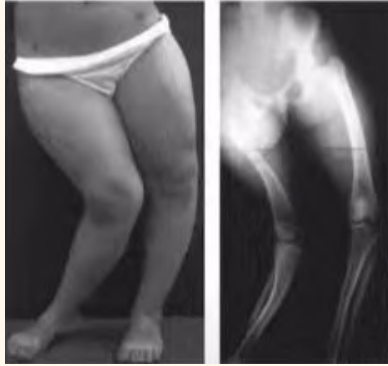
**Ques 55. What is the type of classification used for this fracture and its type?**



- A. Gartland type 3**
- B. Salter Harris type 3**
- C. Gartland type 4**
- D. Salter Harris type 4**

**Ans. A**

**Ques 56. A Child with this deformity. He has recurrent tooth abscesses. Calcium normal, Phosphorus low, PTH normal, ALP high. Diagnosis is?**



- A. Nutritional rickets**
- B. VDDR1**
- C. VDDR2**
- D. Hypophosphatemic rickets**

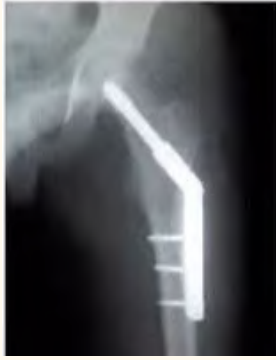**Ans. A**

**Ques 57. A 16 yr old boy claiming as 18 yr old. Which 2 joints should be checked age estimation:**

- A. Wrist and knee**
- B. Hip and elbow**
- C. Hip and knee**
- D. Head and shoulder**

**Ans. A**

**Ques 58. What is the device/ implant shown in this following picture used for femur neck fracture?**



- A. Condylar plate**
- B. Dynamic condylar screw**
- C. Dynamic hip screw**
- D. Locking plate**

**Ans. C**

**Ques 59. Pain in back of leg and thigh after lifting heavy weight. Which segment involved?**

- A. L4**
- B. L5**
- C. L3**
- D. S1**

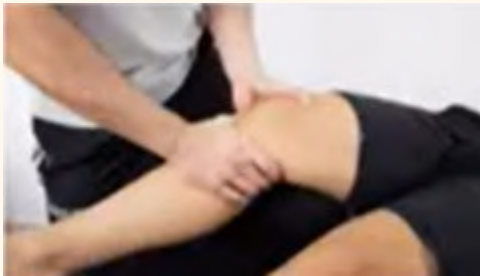**Ans. B**

**Ques 60. Fracture base of 5th metatarsal, below knee cast should be worn for**

- A. 6-8 weeks**
- B. 2-3 weeks**
- C. 16-20 weeks**
- D. 3-5 weeks**

**Ans. A**

**Ques 61. A football player had twist of the knee and ankle, clinically no bony injury was appreciated. Examiner is doing the test as shown her. Which test is this**



- A. Ant drawer for acl**
- B. Post drawer pcl**
- C. Mc murray**
- D. Lachman**

**Ans. D**

**Ques 62. Fracture at which site will affect the longitudinal growth of the bone**

- A. Epiphyseal plate**
- B. Epiphysis**
- C. Metaphysis**
- D. Diaphysis**

**Ans. A**

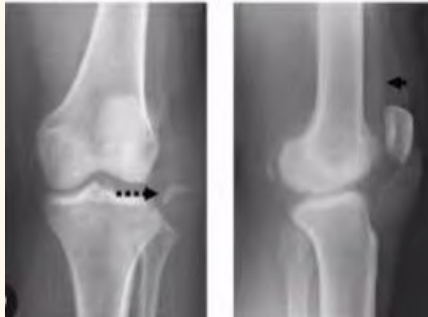**Ques 63. Patient not unable to make "OK" Sign. Which muscle is involved?**

- a. FDS**
- b. FDP**

c. FIC

Ans. b

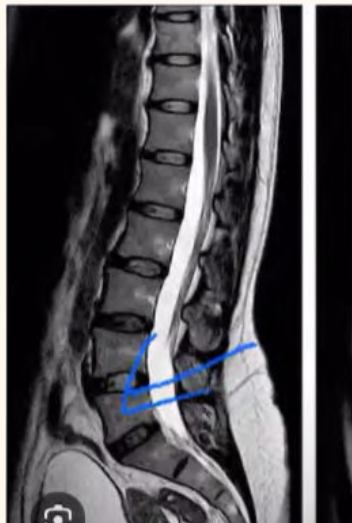**Ques 64. Which area is fracture in the given xray?**



- a. Tibial tuberosity
- b. Medial epicondyle of tibia
- c. Gerdy tubercle

Ans. a

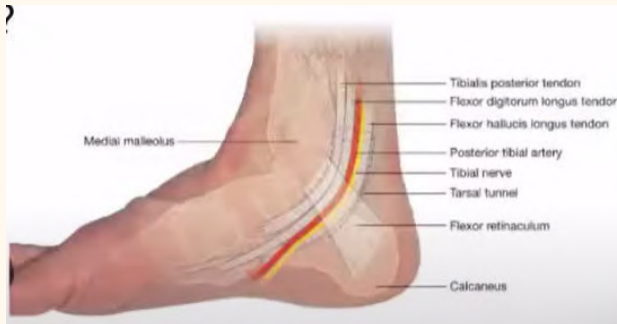**Ques 65. Which nerve will be commonly involved If the injury occurs at the marked levels?**



- a. L4
- b. L5
- c. L2
- d. L3

**Ans.**

**Ques 66. Artery passing between medial malleolus and the Achilles tendon?**



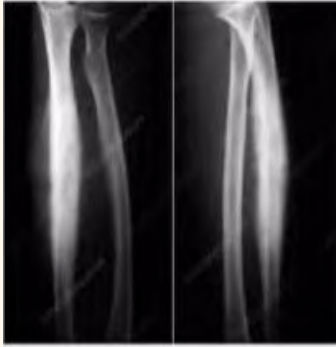**Ans. Posterior tibial artery**

**Ques 67. A child, left femur shaft fracture, managed by plating. Wi**

- a. Creeping substitution
- b. Primary callus
- c. Secondary callus

**Ans. b**

**Ques 68. What is the most likely diagnosis for the lesion shown here?**



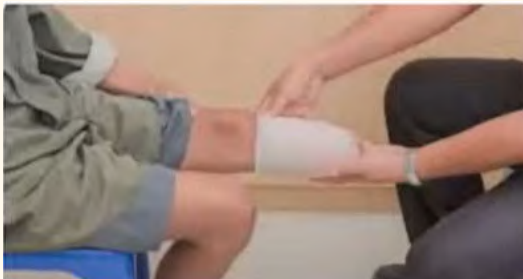**Ans. Sunburst**

**Ques 69. A diaphyseal tumor, probably small round blue cells. Which test/translocation is useful for diagnosis?**

- a. T11,22**
- b. T15,17**

**Ans. a**

**Ques 70. What is the level of amputation shown here?**



**Ans. Below Knee Amputation**

**Ques 71. A 40-year-old RTA case is brought to casualty & declared brought dead by Dr. the Dr informs police official & sends body to mortuary. Autopsy in this case will be conducted on request of**

- A. PP**
- B. Defence lawyer**
- C. Dr**

**D. Investigating officer**

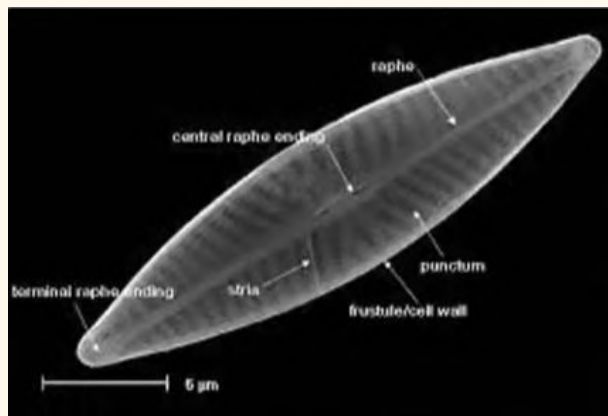
**Ans. D**

**Ques 72. A 30-year-old male dead body was brought for autopsy. The Dr notices greyish white waxy material with preserved facial features. Which is true of following change**

- A. High temperature needed**
- B. Hot & dry environment needed**
- C. Starts very early after death**
- D. It is a form of body preservation by saponification of fats**

**Ans. D**

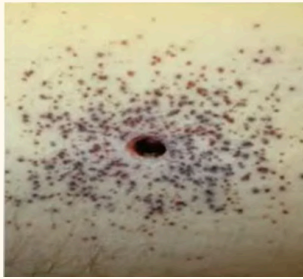**Ques 73. The microscopic image of organism was analyzed in a drowning case. Which is correct about them**



- A. Contains silica & chlorophyll point**
- B. Are microscopic unicellular bacteria**
- C. Present only in bone marrow**
- D. Are not resistant to acids & heat**

**Ans. A**

**Ques 74. The range of fire by a rifled firearm per the image**



- A. Contact**
- B. Close**
- C. Distant**
- D. Cannot be opined**

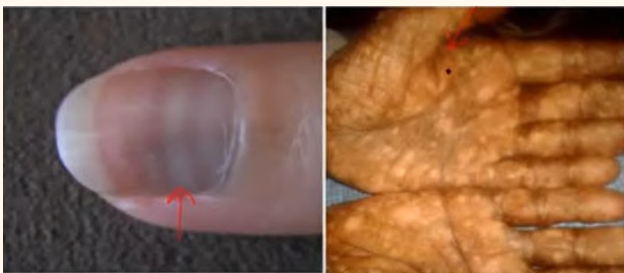**Ans. B**

**Ques 75. A pregnant female comes to a gynecologist who sends her for USG. On USG twin pregnancy noted with about one month difference in age of fetuses. Which is true of following**

- A. Superfetation**
- B. Superfecundation**
- C. Suppositious child**
- D. Posthumous child**

**Ans. A**

**Ques 76. The findings in image is suggestive of which poisoning**



- A. OPC**
- B. Arsenic**
- C. Lead**
- D. Mercury**

**Ans. B**

**Ques 77. Many people have consumed contaminated alcohol and present with abdominal pain, confusion, decreased vision. Methyl alcohol conc detected as 20 mg %. On assessment which metabolites will be found**

- A. Formic acid & lactic acid**
- B Glycolic acid & oxalic acid**
- C. Oxalic acid & formic acid**
- D. Glyoxylic acid & formic acid**

**Ans. B**

**Ques 78. A person comes to emergency after consumption of substance, the form & dose of which is not known to relatives. The patient shows tachypnea, hypotension. On metabolic assessment high anion gap acidosis is noted with hypocalcemia. Diagnosis**

- A. Methyl alcohol**
- B. Ethylene glycol**
- C. Dhatura**
- D. Ethyl alcohol**

**Ans. B**

**Ques 79. 36 yr - G4L3P3- FULL TERM PREG Labor arrested at 8cm cervical dilation. EM CS done after counselling patient. Baby alive but intractable PPH. EM HYSTERECTOMY done to save life of mother**

- A. C
- B. P
- C. T
- D. T

**Ans. A**

**Ques 80. A 30-year-old female abuser with suicidal tendency brought to hospital. Mydriasis, tachypnea, tachycardia +. Diagnosis**

- A. Cocaine
- B. Morphine
- C. Heroin
- D. Chlorpheniramine

**Ans. A**

**Ques 81. MTP in 21-year-old, 10-week pregnancy is to be done by medical methods by using**

- A Intra uterine hyperosmotics
- B Dinoprostone
- C. Oxytocin infusion
- D. M +M

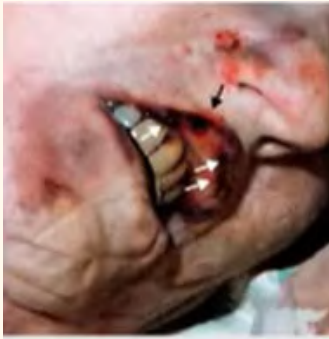**Ans. D**

**Ques 82. A 22 weeks of gestation unmarried 14-year-old girl, who is rape victim comes at your clinic medical termination. What is true for medical abortion?**

- A. MTP can be done in rape victim till 24 wks.
- B. Only one Doctor opinion required
- C. Only done if risk of life
- D. MTP can be done after permission of medical board

**Ans. A**

**Ques 83. This is seen in postmortem examination of which type of asphyxia:**



- A. Throttling**
- B. Smothering**
- C. Hanging**
- D. Garrotting**

**Ans. B**

**Ques 84. Patient from railway station was arrested by police shows symptoms like dilated pupils, sweating, hot skin staggering gait. He suspected to have intoxication of:**

- A. Dhatura**
- B. Cocaine**
- C. Alcohol**
- D. Morphine**

**Ans. A**

**Ques 85. In MTP at 28 weeks for congenital anomalies whose presence is not required:**

- A. Obstetrician**
- B. Lawyer**
- C. Pediatrician**
- D. Sonologist**

**Ans. B**

**Ques 86. A G5P4 women comes for routine sonography for first time, she has early four daughters and want boy this time and ask for sex determination, to be bide to above depicted guidelines what will you choose:**

- A. Will check routine ANC and sex for developmental ABN and do not revile gender to pt**
- B. Will check routine ANC and sex for developmental ABN and do revile gender to pt**
- C. Do revile gender if a girl**
- D. Check only routine ANC, do not check sex**

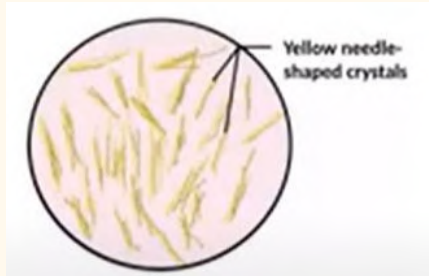
**Ans. A. Will check routine ANC and sex for developmental ABN and do not revile gender to pt**

**Ques 87. A child was born after the death of his father, some of them claimed that the child is not from his biological father, DNA fingerprinting was done to identify the father, and died father was found to be the biological father, this child is called as**

- A. Posthumous child**
- B. Suppositious child**
- C. Illegitimate child**

**Ans. A**

**Ques 88. A child was a victim of sexual assault, test was done using perianal swab, what's the name of this test:**



**Yellow needle shaped crystals**

- A. Barberio test**
- B. Teichman test**
- C. Takayama test**
- D. Florence test**

**Ans. A**

**Ques 89. Which one is correct about sequence of rigor mortis?**

- A. Centre to periphery**
- B. Head to foot**
- C. Foot to head**
- D. Simultaneously**

**Ans. B**

**Ques 90. A sexual assault case in court -"in camera "trial:**

- A. Closed court proceedings**
- B. Recording of proceedings**
- C. Open court proceedings**
- D. Proceeding occurring in different place.**

**Ans. A**

**Ques 91. An 18 yr old male accused of rape claims he is 16 yr old. Which joint X-ray should be done:**

- A. Elbow and ankle**
- B. Knee and wrist**
- C. Shoulder and head**
- D. Hip & knee**

**Ans. B**

**Ques 92. Sour taste is mediated by: - PHYSIOLOGY (PART A)**

- A. TRPV3 Channel**
- B. Metabolic receptors**
- C. Gpcr T1R1**
- D. Gpcr T1Ra**

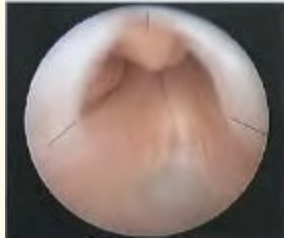**Ans. D**

**Ques 93**

## NEET PG 2024 Question Paper Shift 2

---

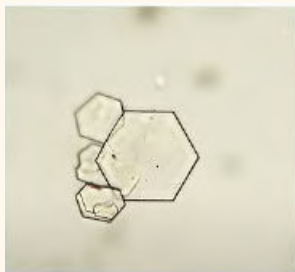
**Ques 1.**What is the management of the endoscopic finding given in an image ?



- a. Stenting
- b. Balloon dilatation.
- c. Fulguration
- d. Internal urethrotomy

**Ans. c**

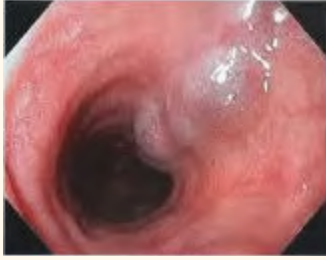**Ques 2.** A young patient presented with recurrent colicky abdominal pain, urine microscopy found to have crystals and RBC, what is the diagnosis ?



- a. Oxalate stone
- b. PKD
- c. Cystine stones
- d. Glomerulonephritis

**Ans. c**

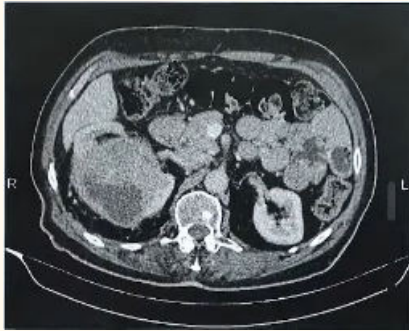**Ques 3.** Identify the image given in UGIE



- a. Barrets esophagus
- b. Esophageal varices
- c. Gastric esrosion

**Ans. b**

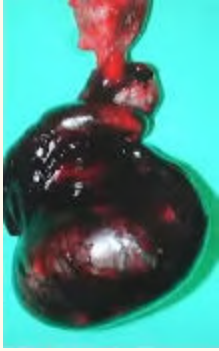
**Ques 4. Identify the disease shown in the image**



- a. PKD
- b. Renal cyst
- c. Medullary sponge kidney
- d. PUJ obstruction

**Ans. b**

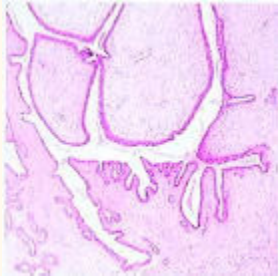
**Ques 5. Q. A 12 years old child presented with sudden severe onset of scrotal najn after an history of trauma 6 hours before. Intra operative image is given what is the likely diagnosis?**



- a. Torsion testis with gangrene
- b. Testicular hematoma
- c. Torsion testis
- d. Gangrene of testis

**Ans. a**

**Ques 6. Q. A 40 years old female with lump in breast measuring 5 X 6 cm with HPE given in the image, what is the likely diagnosis ?**



- a. Phyllodes tumour
- b. Fibroadenoma
- c. Breast carcinoma

**Ans. a**

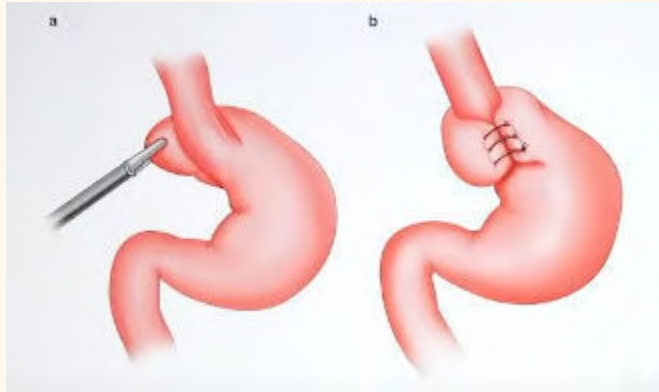
**Ques 7. What is the negative pressure in VAC dressing**

- a. 60-90 mmHg
- b. 90-100 mmHg
- c. 120-130 mmHg

d. 130-150 mmHg

Ans. c

**Ques 8. . Identify the surgery shown in the image**



a. Nissens fundoplication

b. Dor

Ans. a

**Ques 9. Identify the structure marked in the intra operative image of congenital inguinal hernia ?**

a. Femoral vein

b. Obturator vein

c. Testicular vein

d. Inferior epigastric vein

Ans. c

**Ques 10. What biopsy would you take from the lesion shown**

a. Excisional

b. Incisional

c. Edge

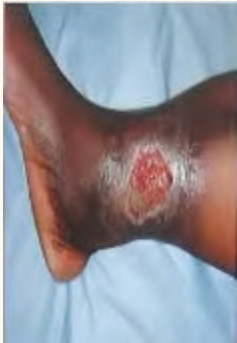**Ans. c**

**Ques 11. How does skin graft derives its nutrition on day 3**

- a. Plasma imbibition**
- b. Inosculation**
- c. Neovascularization**
- d. None**

**Ans. b**

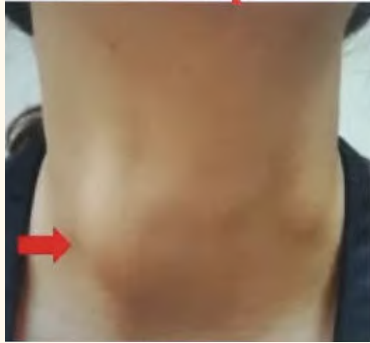**Ques 12. Identify the ulcer**



- a. Arterial**
- b. Venous**
- c. Trophic**
- d. Diabetic foot ulcer**

**Ans. b**

**Ques 13. A 30 years old female presented with the swelling in neck, what is the next step in evaluation ?**



- a. 1131
- b. FNAC
- c. TSII & T4
- d. FSH

**Ans. c**

**Ques 14. Identify the drain in the image**



- a. ROMOVAC
- b. JACKSON PRATT
- c. CORRUGATE
- d. PENROSE

**Ans. a**

**Ques 15. A 5-year-old girl was washing her doll with shampoo containing a chemical Rotenone. Her mother notice her in unconscious state. Which of the following Complex is inhibited by the above-mentioned chemical?**

- A. NADH Dehydrogenase**
- B. Succinate DH**
- C. Cytochrome C**
- D. Cytochrome oxidase**

**Ans. A**

**Ques 16. A patient present with dilated cardiomyopathy on x ray and hypoglycemia, floppy baby, hypotonia, hepatomegaly. What is most likely diagnosis?**

- A. Pompe's disease**
- B. Von Gierke's disease**
- C. Ebstein anomaly**

**Ans. A**

**Ques 17. A 15-year-old child with difficulty in exercise, affected oxidation of long chain fatty acids and biopsy muscle shows fat vacuoles. Which of the following is the diagnosis?**

- A. Carnitine deficiency**
- B. FA synthase defect**
- C. LPL defect**
- D. LDL defect**

**Ans. A**

**Ques 18. A Farmer was on maize as staple diet develops rash on face, neck and hand. Which of the following vitamin should be given in the treatment?**

- A. Niacin
- B. Thiamine

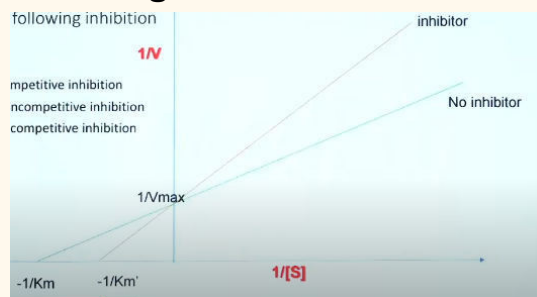
Ans. A

**Ques 19.** A patient develops mouth ulcers on treatment with Methotrexate. Which of the following will decrease with this drug?

- A. UMP
- B. TMP
- C. CMP

Ans. B

**Ques 20.** Increased  $K_m$  and unchanged  $V_{max}$  is seen in which of the following inhibition



- A. Competitive inhibition
- B. Noncompetitive inhibition
- C. Uncompetitive inhibition

Ans. A

**Ques 21.** A drug is given for the treatment of hyperlipidemia. Facial flushing was noted. Which of the following drug causes this side effect?

Ans. Nicotinic acid

**Ques 22. Increased chylomicron, lipemic serum is seen in.**

**Ans. Lipoprotein lipase deficiency**

**Ques 23. Which micronutrient deficiency causes anemia, gum bleeding and x ray changes - White frankel line?**

- A. Copper**
- B. Iron**
- C. Zinc**

**Ans. B**

**Ques 24. Which of the following enzyme is deficient in patient with Phenylketonuria if phenylalanine hydroxylase level is normal**

**Ans. Dihydrobiopterine reductase**

**Ques 25. A tall stature, long digits, long arm span and subluxation of lens is seen in which of the following defect**

- A. Fibrillin 1**
- B. Collagen**

**Ans. A**

**Ques 26. A male patient with pallor, weakness and easy fatigability. His blood report shows MCV 53, TIBC- Increased. What is your diagnosis?**

**Ans. Iron deficiency anemia**

**Ques 27. Which of the following is methanol poisoning derivatives?**

- A. Formic acid+ Lactic acid**
- B. Acetic acid**

**Ans. A**